

VIDEOS IN CLINICAL MEDICINE  
SUMMARY POINTS

## Clinical Examination of the Shoulder

Holly Beach, M.D., and Paul Gordon, M.D., M.P.H.

*The following text summarizes information provided in the video.***OVERVIEW**

Shoulder pain leads many patients to see a primary care physician. Obtaining a focused history and performing a proper examination of the shoulder facilitate diagnosis and treatment. This video reviews the anatomy of the shoulder, common shoulder injuries, and the procedures for obtaining the patient's history and performing a physical examination of the shoulder.

**ANATOMY**

A thorough understanding of the anatomy of the shoulder is crucial for a good clinical examination. The major anatomical landmarks of the shoulder include the clavicle, the acromion, the acromioclavicular joint, the humerus, the subacromial space, the rotator cuff (including the supraspinatus, infraspinatus, and teres minor on the posterior aspect of the scapula and the subscapularis on the anterior aspect of the scapula), the deltoid muscle, and the biceps tendon (Figs. 1, 2, and 3).

**HISTORY**

The patient history is an essential component of the evaluation of shoulder pain. Obtain a focused history. Ask the patient when the pain began, what makes it better or worse, how severe it is, and whether it radiates. Ask whether there are associated symptoms, whether the pain began after trauma or repetitive use, whether the pain is worse during overhead movements, such as lifting or reaching for something, and whether the pain decreases with rest, exercise, or medication.

**SHOULDER EXAMINATION**

Examination of the shoulder involves inspection, palpation, assessment of range of motion, and the performance of various special maneuvers.<sup>1</sup>

*Inspection*

Fully expose the affected shoulder to permit visualization of the anterior, posterior, and lateral aspects. Inspect the skin for ecchymosis and for rash and redness, which may suggest cellulitis. The presence of a scar may indicate previous trauma or surgery. Atrophy of the musculature may be the result of a chronic tear of the rotator cuff or of neurologic impairment.<sup>2</sup> The acromioclavicular joint should also be visualized. Elevation of the clavicle may represent an acromioclavicular sprain, also known as a shoulder separation.

*Palpation*

Palpate specific anatomical structures of the shoulder. Palpation may help you to identify the affected areas. Begin with palpation of the sternoclavicular joint and assess for tenderness, deformity, or increased movement in the affected shoulder as compared with the unaffected shoulder.

From the Department of Family and Community Medicine, University of Arizona College of Medicine, Tucson. Address correspondence to Dr. Beach at the Department of Family and Community Medicine, University of Arizona, 2800 E. Ajo Way, Tucson, AZ 85713, or at holly.beach@bannerhealth.com.

N Engl J Med 2016;375:e24.

DOI: 10.1056/NEJMvcm1212941

Copyright © 2016 Massachusetts Medical Society.

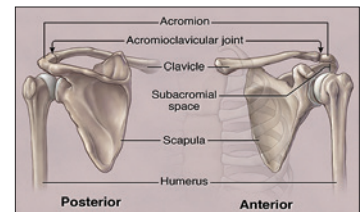


Figure 1. Greater Tubercle.

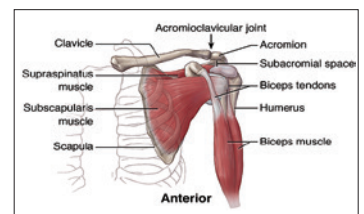


Figure 2. Anterior View of the Shoulder.

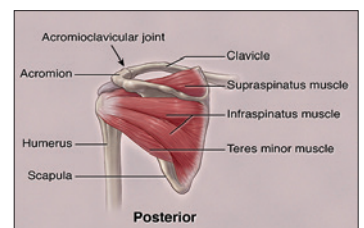


Figure 3. Posterior View of the Shoulder.

Continue to palpate, moving from the proximal to the distal clavicle and paying particular attention to the acromioclavicular joint and the acromioclavicular ligament. Acute tenderness in this region may represent an acromioclavicular sprain or acromioclavicular joint separation. In patients with a history of chronic pain, tenderness in this region suggests osteoarthritis.

Next, palpate the acromion and the subacromial space. Tenderness in this region may suggest subacromial impingement or injury of the supraspinatus tendon. Subacromial impingement is caused by compression of the rotator cuff, the subacromial bursa, and other soft-tissue structures between the humeral head and the undersurface of the acromion.

Palpate the biceps tendon and the muscle in the bicipital groove. Tenderness may indicate bicipital tendinopathy. Again, note any differences between the affected and unaffected shoulders. In bicipital tendinopathy, the patient may have tenderness in both shoulders. Pain may increase on palpation of the affected shoulder if bicipital tendinopathy is present.

#### *Range of Motion*

Evaluate the range of motion in forward flexion, abduction, external rotation, and internal rotation. If the patient has full active range of motion, there is no need to assess the passive range of motion. However, if the patient does not have full range of motion, assistance should be provided. Loss of active and passive ranges of motion in all planes, especially during external rotation, is characteristic of adhesive capsulitis, but it may also represent advanced osteoarthritis of the glenohumeral joint.

The sensation of pain on active abduction of the arm between 60 and 100 degrees away from the body may be associated with rotator-cuff injury. Pain in this region during both active and passive abduction suggests subacromial bursitis.

#### *Assessment of the Rotator Cuff*

The muscles of the rotator cuff are the supraspinatus, infraspinatus, teres minor, and subscapularis. The supraspinatus muscle allows abduction of the arm. Test its function using the empty-can test. Have the patient abduct the arms to 90 degrees, with palms facing the floor. Then ask the patient to rotate the arms forward, so the thumbs point downward — as if the patient were emptying a can of liquid. Apply downward pressure on the arms, and ask the patient to resist the pressure. Weakness in the affected shoulder as compared with the unaffected shoulder may indicate injury of the supraspinatus muscle, possibly caused by overuse, tendinopathy, or a tear.

The infraspinatus and teres minor muscles each contribute to external rotation of the arm. These muscles can be tested simultaneously. Have the patient flex the arm to 90 degrees at the elbow, with the upper arm positioned at the patient's side. As you apply resistance, ask the patient to rotate the arm outward. Weakness in the affected shoulder may indicate a tear or tendinopathy in the infraspinatus or teres minor muscle. It is important to stabilize the patient's elbow with your hand during this examination. Weakness or pain in the affected shoulder suggests injury of the infraspinatus muscle.

The subscapularis muscle allows internal rotation of the shoulder. Test this muscle with the subscapularis liftoff test. Place the patient's hand on the patient's lower back and ask him or her to rotate the shoulder inward, against resistance. Inability to lift the hand off the back may indicate a tear or tendinopathy in the subscapularis muscle.<sup>3</sup>

#### *Subacromial Bursitis and Assessment of Impingement*

Inflammation of the subacromial bursa can lead to pain and limited range of motion, especially when the patient is performing overhead maneuvers. The Hawkins–

Kennedy test is used to assess the subacromial bursa. Have the patient flex the elbow to 90 degrees. Elevate the patient's shoulder to a 90-degree, forward-flexed position and then internally rotate the arm. Pain with this maneuver may indicate subacromial impingement.<sup>4</sup>

An additional test for subacromial impingement is Neer's test. To perform this test, rotate the patient's arm internally and raise it. If the maneuver is painful, the test is positive and may indicate subacromial bursitis.

#### *Assessment of the Acromioclavicular Joint*

The cross-body adduction test, also known as the crossover test, is used to evaluate the acromioclavicular joint. Adduct the patient's arm across the body. Pain in the region of the acromioclavicular joint may indicate sprain, separation, or osteoarthritis.

#### *Testing for Instability*

To test for anterior shoulder instability, place the patient in the supine position. Abduct the patient's arm to 90 degrees and then flex the elbow to 90 degrees. Apply pressure to externally rotate the shoulder further. If this maneuver induces a sense of instability or fear — or the appearance of apprehension — in the patient, the test, referred to as the apprehension test, is considered to be positive. Next, apply pressure to the shoulder, pressing in a posterior direction. If this force alleviates symptoms, then the relocation test is positive and constitutes another indication of shoulder instability. In a patient with suspected anterior shoulder instability, perform this test gently, and limit the force applied so as not to dislocate the shoulder while conducting the test.

#### *Assessment of the Biceps*

The biceps muscle supinates and flexes the forearm. Inflammation of the long head of the biceps can cause anterior shoulder pain. Use Speed's test to assess the biceps by extending the patient's elbow, supinating the forearm, and then flexing the arm forward while applying opposing force. If the patient has pain in response to this maneuver, bicipital tendinopathy may be the cause. You can also perform Yergason's test to evaluate the biceps. Flex the patient's elbow to 90 degrees and supinate the forearm against resistance. Pain with this maneuver suggests bicipital tendinopathy.

### **COMMON SHOULDER INJURIES**

#### *Impingement Syndrome*

Subacromial impingement of the rotator-cuff tendons, the subacromial bursa, and other soft-tissue structures between the greater tubercle of the humeral head and the lateral acromion is the most common cause of shoulder pain seen by primary care clinicians.<sup>5</sup> Repetitive overhead motions, such as painting or swimming, most often induce this injury. To test for subacromial impingement, evaluate the range of motion and perform Neer's test and the Hawkins–Kennedy test.

#### *Injuries to the Rotator Cuff*

The rotator cuff is composed of four tendons: the supraspinatus tendon, which allows the arm to abduct (especially for the first 15 degrees), the infraspinatus and teres minor tendons, which allow the arm to rotate externally, and the subscapularis tendon, which allows the shoulder to rotate internally. Rotator-cuff injuries are common.

#### *Osteoarthritis*

Osteoarthritis of the glenohumeral joint is caused by wearing of the hyaline cartilage of the glenoid, the humeral head, and the labrum. Patients with a history of a

## REFERENCES

1. Woodward TW, Best TM. The painful shoulder: part I. Clinical evaluation. *Am Fam Physician* 2000;61:3079-88.
  2. Brown KE, Stickler L. Shoulder pain and dysfunction secondary to neural injury. *Int J Sports Phys Ther* 2011;6:224-33.
  3. Rigsby R, Sitler M, Kelly JD. Subscapularis tendon integrity: an examination of shoulder index tests. *J Athl Train* 2010;45:404-6.
  4. Makhni EC, Ahmad CS. 5 Points on Shoulder Examination of the Overhead Athlete. *Am J Orthop (Belle Mead NJ)* 2015;44:347-52.
  5. Khan Y, Nagy MT, Malal J, Waseem M. The painful shoulder: shoulder impingement syndrome. *Open Orthop J* 2013;7:347-51.
  6. Burbank KM, Stevenson JH, Czarnecki GR, Dorfman J. Chronic shoulder pain: part I. Evaluation and diagnosis. *Am Fam Physician* 2008;77:453-60.
  7. Gorski JM, Schwartz LH. Shoulder impingement presenting as neck pain. *J Bone Joint Surg Am* 2003;85-A:635-8.
- Copyright © 2016 Massachusetts Medical Society.

shoulder dislocation, a fracture, or a large rotator-cuff tear are at increased risk for the development of osteoarthritis in the glenohumeral joint. Osteoarthritis is characterized by progressively worsening pain during active and passive range-of-motion exercises. It can be tested by assessing the range of motion.

*Adhesive Capsulitis*

Adhesive capsulitis, also known as frozen shoulder, is characterized by a painful, stiff shoulder and by loss of range of motion of the glenohumeral joint.<sup>6</sup> Any injury or impairment that results in a decreased ability to use the shoulder can progress to adhesive capsulitis. Rotator-cuff tendinopathy and fractures and other conditions that result in immobilization, such as stroke, can precede adhesive capsulitis. The use of a sling and a lack of exercise can also contribute to the development of this condition.

To test for frozen shoulder, evaluate active and passive ranges of motion, especially external rotation. Painful, limited external rotation is a strong indication of adhesive capsulitis. Radiography is commonly used as part of the evaluation for adhesive capsulitis. However, in contrast with the radiographic findings for osteoarthritis, in patients with adhesive capsulitis, the findings often appear to be normal.

**PITFALLS OF SHOULDER EXAMINATION**

There are several common pitfalls in the performance of the shoulder examination. It is important to view both shoulders completely and simultaneously. A full view is necessary to ensure that deformities and asymmetries are not overlooked.

Consider the possibility that shoulder pain may be referred pain from the neck.<sup>7</sup> For example, a patient with cervical radiculopathy may present with shoulder pain, but the cervical radiculopathy may not be diagnosed unless an examination of the cervical spine and a neurologic examination are performed. Pain that is initiated in the cervical spine generally localizes to the lateral neck and trapezius, whereas pain coming from the shoulder joint or rotator cuff commonly localizes to a lower point in the deltoid and the upper arm. Further discussion and examination of neck-related pain are beyond the scope of this video.

Serious conditions such as shoulder dislocation and adhesive capsulitis can be overlooked if range of motion is not fully assessed. Thus, always test passive range of motion in a patient who has a limited active range of motion.

**TREATMENTS**

Treatments for shoulder pain are multifactorial and depend on the cause of the condition. However, in general, treatments for common shoulder conditions are likely to consist of a combination of recommendations, including rest, the avoidance of aggravating activities, the use of antiinflammatory drugs, physical therapy, and in some cases glucocorticoid injections. On rare occasions, surgery is indicated.

**SUMMARY**

The first steps in the evaluation of shoulder pain include obtaining a thorough history and performing a physical examination, both of which allow the clinician to form an accurate diagnosis. To confirm the diagnosis, it may be necessary to obtain radiographs, magnetic resonance imaging scans, or ultrasound images. Referral to specialists may also be appropriate for diagnostic purposes or treatment.

No potential conflict of interest relevant to this article was reported.

Disclosure forms provided by the authors are available with the full text of this article at NEJM.org.