

# Corticolimbic Blood Flow During Nontraumatic Emotional Processing in Posttraumatic Stress Disorder

K. Luan Phan, MD; Jennifer C. Britton, MS; Stephan F. Taylor, MD; Lorraine M. Fig, MD; Israel Liberzon, MD

**Context:** Recent brain imaging studies implicate dysfunction of limbic and paralimbic circuitry, including the amygdala and medial prefrontal cortex (MPFC), in the pathogenesis of posttraumatic stress disorder (PTSD) during traumatic recollection and imagery. However, the relationship between activity in these regions and general emotional processing unrelated to traumatic experience has not been fully examined.

**Objective:** To investigate activity in the limbic and paralimbic brain regions in PTSD in response to a challenge with emotionally salient generic visual images.

**Design:** Cross-sectional, case-control study.

**Setting:** Academic medical center.

**Participants:** Sixteen Vietnam veterans with combat-related PTSD (PTSD group), 15 combat-exposed Vietnam veterans without PTSD (combat control group), and 15 age- and sex-matched healthy controls (normal control group).

**Main Outcome Measures:** We used positron emission tomography to study regional cerebral blood flow

while participants viewed complex visual pictures with negatively valenced/aversive, nonaversive (“neutral”), and blank pictures. Psychophysiologic and emotional self-report data were also recorded.

**Results:** All 3 groups activated the dorsal MPFC to general salient content. Controls without PTSD activated the left amygdala in response to aversive stimuli. Normal controls activated the ventral MPFC and combat-exposed non-PTSD and PTSD participants exhibited either no response or deactivation in these regions, respectively, during negative emotional experience.

**Conclusions:** Consistent with current functional neuroanatomic models, patients with PTSD exhibited altered neural responses in the amygdala and ventral MPFC during the processing of emotionally salient but trauma-unrelated stimuli, potentially reflecting disorder-specific changes. Activation of the amygdala and lack of ventral MPFC deactivation to negatively valenced images in combat controls may reflect compensatory changes after trauma exposure that are not associated with PTSD.

*Arch Gen Psychiatry.* 2006;63:184-192

## Author Affiliations:

Department of Psychiatry, Pritzker School of Medicine, The University of Chicago, Chicago, Ill (Dr Phan); Neuroscience Program, University of Michigan (Dr Liberzon and Ms Britton), Department of Psychiatry, University of Michigan Medical School (Drs Taylor and Liberzon), and Nuclear Medicine Service (Dr Fig) and Psychiatry Service (Dr Liberzon), Veterans Administration Medical Center, Ann Arbor.

**P**OSTTRAUMATIC STRESS DISORDER (PTSD) can occur after trauma exposure (eg, combat, assault, and disasters), and it is characterized by various altered emotional responses. Patients with PTSD not only experience intense negative emotional reactions when reminded of their trauma but also report anhedonia, social withdrawal, isolation, and decreased emotional expressivity, referred to as “emotional numbing.”<sup>1</sup> Characterizing the neural basis of these diverse, distorted emotional responses poses a major challenge to contemporary psychiatric research.

Functional neuroimaging techniques, such as positron emission tomography (PET) and functional magnetic resonance imaging, provide an opportunity to examine the neural correlates of these altered emotional responses in PTSD.<sup>2-6</sup> To

date, studies have focused primarily on brain activation in response to trauma-related stimuli. Exposure to combat sights and sounds in combat veterans with PTSD has been associated with relatively increased amygdala activation<sup>7,8</sup> and relatively decreased ventral medial prefrontal cortex (MPFC) or subcallosal anterior cingulate cortex (ACC) activation.<sup>9</sup> The recollection/imagery of combat and civilian traumatic events in PTSD has been associated with amygdala, orbitofrontal cortex (OPFC), and insular cortex<sup>10</sup> activation and relatively decreased blood flow in the MPFC or ACC.<sup>11-14</sup> These findings are central to current functional neuroanatomic models of PTSD<sup>2-6</sup> and are supported by findings from animal experiments, lesion studies, and functional imaging in healthy individuals. These studies<sup>15-18</sup> collectively implicate the same paralimbic (insula, MPFC, and OPFC) and

limbic (amygdala and ACC) regions in perceiving and responding to emotionally salient stimuli and affective regulation. Although limbic and paralimbic frontal dysfunction has been consistently linked to trauma-related symptom provocation in PTSD,<sup>2-5</sup> it remains unclear whether a similar neural pattern extends to nontraumatic probes. Do abnormal emotional responses “generalize” to nonspecific stimuli? The use of generic emotional stimuli that are not linked to an individual’s trauma may thus be informative.

Initial findings of abnormal responses to emotional stimuli not related to trauma in PTSD point toward the same regions. Patients with PTSD exhibit exaggerated amygdala activity to masked<sup>19</sup> and overtly presented<sup>20</sup> fearful faces, suggesting an abnormal amygdala response to general threat-related stimuli. In the study<sup>20</sup> using overtly presented fearful faces, a diminished MPFC response was also observed. Previously, Shin et al<sup>21</sup> observed that PTSD subjects, unlike controls, did not activate the rostral ACC and MPFC in response to general negative words in an emotional Stroop paradigm. Similarly, Bremner and colleagues<sup>22</sup> reported that during the retrieval of emotional words, the PTSD group exhibited deactivations/decreased regional cerebral blood flow (rCBF) throughout the frontal brain areas (ACC, OPFC, and MPFC). These findings, although implicating limbic and paralimbic involvement in affective dysfunction in PTSD, may reflect more perceptual or cognitive aspects of emotion than affective experience itself. Lanius and colleagues<sup>23</sup> included traumatic and nontraumatic emotional life events in a script-driven imagery study and reported lower ACC activation in PTSD across all imagery conditions.

Unlike emotional faces or words, complex visual pictures from the International Affective Picture System<sup>24</sup> directly elicit emotional experience and response.<sup>25</sup> Furthermore, these standardized pictures contain emotionally salient content unrelated to personal traumatic experience and, therefore, are suited for the investigation of general emotional experience. These emotional pictures serve as reliable probes of the paralimbic and limbic brain regions<sup>26-31</sup> implicated in models of PTSD.<sup>2-6</sup>

In this PET activation study, we probed neural activity during general affective experience in PTSD by examining response to generally aversive (trauma-unrelated) visual stimuli. We studied individuals with PTSD in relation to 2 separate comparison groups: healthy controls never exposed to trauma and trauma-exposed individuals without PTSD. To our knowledge, this is the first large-sample functional imaging study of affective processing of emotional pictures comparing all 3 groups. We hypothesized that patients with PTSD would have differential responses to emotionally salient stimuli specifically in the amygdala, ACC, and paralimbic cortex (dorsal MPFC, ventral MPFC/OPFC, and insular cortex) relative to controls.

## METHODS

### PARTICIPANTS

Sixteen Vietnam veterans with combat-related PTSD (PTSD patients), 15 Vietnam combat-exposed veterans without PTSD (combat controls [CCs]), and 15 healthy age- and sex-matched indi-

**Table 1. Characteristics of the 3 Participant Groups**

	Normal Controls (n = 15)	Combat Controls (n = 15)	PTSD Patients (n = 16)
Age, mean ± SD, y	48.7 ± 8.0	56.5 ± 4.9	53.8 ± 4.2
Ethnicity, No.			
White	13	15	16
Black	2	0	0
Previous comorbid diagnoses, No.*			
Depressive disorder	0	0	3
Panic/anxiety disorder	0	0	1
Substance abuse/dependence	3	1	5
Symptom scores, mean ± SD†			
CAPS‡	2.8 ± 3.4	6.3 ± 7.3	61.3 ± 19.9
IES-R	35.5 ± 15.1	35.9 ± 14.7	68.4 ± 20.8
DES	4.3 ± 2.8	6.4 ± 4.7	21.7 ± 13.4
TAS	58.4 ± 7.7	52.5 ± 7.9	71.9 ± 15.5
BDI	4.5 ± 4.2	5.2 ± 4.9	21.3 ± 9.9
STAI-state	29.5 ± 8.5	28.0 ± 8.4	45.6 ± 17.7
STAI-trait	30.3 ± 7.3	30.1 ± 7.9	49.5 ± 15.9

Abbreviations: BDI, Beck Depression Inventory; CAPS, Clinician-Administered Posttraumatic Stress Disorder Scale; DES, Dissociative Experiences Scale; IES-R, Impact of Events Scale-Revised; PTSD, posttraumatic stress disorder; STAI, State-Trait Anxiety Inventory; TAS, Toronto Alexithymia Scale.

\*Normal control subjects: alcohol dependence (n = 1) and alcohol abuse (n = 2); combat control subjects: alcohol abuse (n = 1); and patients with PTSD: major depression (n = 3), anxiety disorder not otherwise specified (n = 1), alcohol dependence (n = 4), and cannabis dependence (n = 2).

†Significant between-group differences ( $P < .001$  for all) from 1-way analyses of variance.

‡Eleven of the 16 patients with PTSD had a CAPS score greater than 50, and 15 of 16 patients with PTSD had a CAPS score greater than 40.

viduals without previous trauma exposure (normal controls [NCs]) participated in this study. The data from 1 PTSD patient were corrupted and omitted from subsequent analysis. The PTSD diagnosis and evaluation of other Axis I psychiatric disorders were established using the *Structured Clinical Interview for DSM-IV*.<sup>32</sup> Besides the PTSD diagnosis in the PTSD group, all the participants were free of current Axis I disorders. All the participants were right-handed and had not been taking psychotropic medications for at least 4 weeks before the study (6 weeks in the case of fluoxetine and antipsychotic medications). The participants had no history of major medical or neurologic illness, and those with histories of substance abuse or dependence were in remission for at least 6 months. To control for potentially confounding effects of past illicit drug use or abuse, we recruited controls matched for substance use history to PTSD patients. Results of urine toxicology screens were negative for all the participants. Magnetic resonance imaging confirmed the absence of any structural abnormalities. All the participants gave written informed consent after explanation of the experimental protocol, as approved by the University of Michigan institutional review board and the Ann Arbor Veterans Administration Medical Center subcommittee on human subjects.

As seen in **Table 1**, the groups had similar ethnic backgrounds and past psychiatric comorbidity. All the participants were aged 35 to 60 years. The ages of the PTSD patients were not significantly different from those of either control group; however, the CC group was older than the NC group ( $F_{2,3} = 6.646$ ;  $P = .003$ ). The PET data analysis comparing controls incorporated age as a nuisance variable to account for this difference.

## ACTIVATION PROTOCOL AND PET PROCEDURE

### Stimuli

The emotional activation paradigm has been previously reported.<sup>33</sup> Participants viewed 2 sets of complex International Affective Picture System gray-scaled images: an aversive set containing negatively valenced/unpleasant images and a nonaversive set containing images of neutral valence. The sets were matched with respect to the presence of faces and human figures. Another set of blank images consisted of gray screens with a fixation cross, serving as a low-level control condition. All the image sets were matched on luminance using image-editing software (Photoshop 4.0; Adobe Systems, Mountain View, Calif).

### Stimulus Presentation and Behavioral Task

We acquired PET, psychophysiologic, and behavioral ratings data while participants viewed blocks of aversive, neutral, or blank images. Fourteen images per block were displayed for 5 seconds each, with no interstimulus interval; no pictures were presented more than once. Data acquisition consisted of 2 runs of the 3 conditions (aversive, nonaversive, and blanks), counterbalanced across participants. During scanning, participants verbally rated each picture for aversive content on a 5-point scale from 1 (not at all unpleasant) to 5 (extremely unpleasant). During the blank condition, participants used a rating of 3 for each blank screen. We chose this appraisal/labeling task to support task compliance in the absence of empirical evidence that it could affect corticolimbic blood flow, as recently reported (see the "Comment" section).<sup>34</sup> The participants also participated in a script-driven imagery paradigm in a separate experiment, reported elsewhere.<sup>35</sup> The order of the experiments was counterbalanced across participants.

### Psychophysiologic Measures

Skin conductance was recorded using a psychophysiologic monitoring system (model MP-100; BioPac Systems, Santa Barbara, Calif) and silver-silver chloride electrodes attached to the finger volar surface. Waveform peak and integral during image presentation were analyzed. Subjective ratings and skin conductance responses were analyzed using separate  $3 \times 3$  (group [NCs, CCs, and PTSD patients]  $\times$  condition [aversive, nonaversive, and blank]) analyses of variance.

### PET Data Acquisition and Analysis

The PET procedures have been described previously.<sup>33</sup> In brief, PET was performed using the Siemens ECAT EXACT and HR+ scanners (CTI Molecular Imaging Inc, Knoxville, Tenn), which yield 47 or more sections simultaneously for whole-brain coverage at an axial field of view of approximately 15 cm and a resolution of 4.5 mm full-width half-maximum. Although both scanners have similar technical specifications, any differences between them were minimized as follows: (1) an algorithm derived from point-source calculations (as supplied by CTI) was performed on data acquired from the HR+ scanner to equate sensitivities; (2) data were reconstructed using the same 0.5 Hanning filter to yield an effective full-width half-maximum of 10 to 11 mm; (3) data were collected on the same number of participants in each group using each scanner (EXACT: 10 PTSD patients, 10 CCs, and 11 NCs; HR+: 6 PTSD patients, 5 CCs, and 4 NCs); (4) statistical analysis was based on

intrasubject subtraction (comparisons within subjects with fixed-effects first-level analyses); and (5) scanner type was entered as a categorical nuisance variable into the analysis and confirmed that scanner type did not affect any of the activation foci reported in the "Results" section.

Participants were positioned in the PET scanner gantry, using the orbitomeatal line as a reference and a forehead restraint to reduce intrascanner movement. For each PET scan, 10 to 15 mCi of [<sup>15</sup>O]H<sub>2</sub>O was given as an intravenous bolus. Data were collected in 3-dimensional acquisition mode as a single 60-second frame beginning 2 seconds after the radioactivity arrived in the brain. Lights were dimmed, and ambient noise (from cooling fans) was minimal. Scans were separated by 12 minutes. Stimuli presentation began 5 seconds before image acquisition.

All PET images of integrated tissue counts were decay corrected and reconstructed using filtered back-projection with a Hanning filter to yield an effective full-width half-maximum of 10 to 11 mm, with standard attenuation and scatter correction.<sup>33</sup> The PET data were analyzed using statistical parametric mapping (SPM99; Wellcome Department of Cognitive Neurology, London, England). The PET images were realigned to the first image in the scanning session, spatially normalized to the Montreal Neurological Institute brain template, adjusted for global values, and smoothed using an isotropic Gaussian filter of 12-mm width (full-width half-maximum). The data were fit to a general linear statistical model according to standard processing methods.<sup>36-39</sup> Hypotheses were tested as contrasts in which linear combinations of the model parameters were evaluated using *t* statistics. Relevant contrasts between conditions (nonaversive vs blank and aversive vs nonaversive) were first performed for each participant<sup>37</sup> and then entered into a second-level random-effects within-group analysis using a 1-sample *t* test on contrast images obtained in each participant for each comparison of interest, treating participants as a random variable.<sup>40</sup> We used a conservative random-effects analysis designed to permit general population inferences and between-group comparisons. Resulting statistical parametric maps of the *t* statistic at each voxel were transformed into *z* scores. We had a priori hypotheses about differential activation between groups in specific brain regions (amygdala, insula, ACC, MPFC, and OPFC) and, therefore, using the small-volume correction toolbox in SPM99, we examined significant activations in a search area covering 672 mL of brain tissue comprising 2 volumes: (1) one with dimensions of 140  $\times$  60  $\times$  50 mm centered at [0, -10, -5] to cover the amygdala and insula and (2) another with dimensions of 40  $\times$  70  $\times$  90 mm centered at [0, 35, 15] to cover the entire medial wall of the frontal cortex (ACC, MPFC, and OPFC). For the within-group analysis, activation foci in this search volume were considered significant if they survived a  $P < .005$  corrected for multiple comparisons using the false discovery rate procedure in SPM99 such that only 5 of every 1000 voxels are falsely accepted as significant,<sup>41</sup> with a cluster extent threshold (*k*) of greater than 5 contiguous voxels. For the between-group analysis, we first performed an omnibus *F* test for a group effect to test for the presence of activations in a priori regions before any post hoc pairwise *t* tests (eg, NC > PTSD patients). Only foci that exhibited a significant effect of group in the omnibus test were considered to be significant in subsequent between-group comparisons. Significance thresholds for a priori regions exhibiting between-group differences (2-sample *t* tests) were set at the same level ( $P < .005$ , false discovery rate corrected for multiple comparisons). Outside a priori regions, we report activations surviving correction for multiple comparisons across the entire brain (false discovery rate-corrected  $P < .005$ ).

We also performed a correlational analysis to determine whether clinical symptoms of PTSD patients were associated with rCBF patterns. Beck Depression Inventory, Clinician-

Administered Posttraumatic Stress Disorder Scale, and Toronto Alexithymia Scale scores were entered as covariates of interest in the whole-brain voxelwise analysis. In addition, interregional correlation analyses in each group examined the relationship between rCBF responses in the left amygdala and the rest of the brain given recent evidence of a functional relationship between the amygdala and prefrontal regions (ACC and MPFC) in PTSD.<sup>42-44</sup> Data extracted from a functional region of interest in the left amygdala (MNI [Montreal Neurologic Institute] coordinates: [-16, -6, -28]), which was observed to

be differentially activated in the NC and PTSD groups, was correlated with whole-brain, voxelwise changes in rCBF for the aversive vs nonaversive contrast.

## RESULTS

### PSYCHOPHYSIOLOGIC AND SUBJECTIVE RESPONSES

Aversive pictures were rated more negatively than neutral pictures ( $F_{1,43}=231.4$ ;  $P<.001$ ); between-group differences ( $P=.64$ ) and group  $\times$  condition interactions ( $P=.78$ ) were not significant. Aversive pictures also elicited a greater skin conductance response ( $F_{2,42}=15.8$ ;  $P<.001$ ); between-group differences and group  $\times$  condition interactions were not significant ( $P=.91$  and  $P=.92$ , respectively) (**Table 2**).

### [<sup>15</sup>O]H<sub>2</sub>O PET RESULTS

Within-group analyses focused on the amygdala, insula, and medial frontal cortex as a priori regions of interest. The omnibus F test for a group main effect did not reveal any significant foci in the nonaversive vs blank contrast. For the aversive vs nonaversive contrast, a group effect was detected in the amygdala ([-18, -8, -28];  $z=2.65$ ;  $P<.005$ ) and in the ventral MPFC ([-8, 58, -20];  $z=2.64$ ;  $P<.005$ ) (**Table 3** and **Table 4**).

**Table 2. Behavioral and Psychophysiologic Measures\***

	Pictures		
	Blank	Nonaversive	Aversive
Normal controls			
Subjective valence rating	NA	1.05 $\pm$ 0.10	3.5 $\pm$ 0.69
Skin conductance, peak	0.38 $\pm$ 0.40	0.70 $\pm$ 0.62	1.00 $\pm$ 0.78
Combat controls			
Subjective valence rating	NA	1.07 $\pm$ 0.11	3.27 $\pm$ 1.13
Skin conductance, peak	0.47 $\pm$ 0.49	0.73 $\pm$ 0.65	1.02 $\pm$ 0.89
PTSD patients			
Subjective valence rating	NA	1.17 $\pm$ 0.25	3.58 $\pm$ 1.19
Skin conductance, peak	0.43 $\pm$ 0.67	0.58 $\pm$ 0.68	0.95 $\pm$ 1.21

Abbreviations: NA, not applicable; PTSD, posttraumatic stress disorder.

\*Data are given as mean  $\pm$  SD of subjective valence ratings (1 = not at all unpleasant and 5 = extremely unpleasant) and skin conductance measurements (expressed as peak in micromho). Significant main effect of condition ( $P<.001$ ) for valence ratings and skin conductance response.

**Table 3. Areas of Increased Blood Flow During Emotional Processing of Pictures**

	Normal Controls			Combat Controls			PTSD Patients		
	x, y, z*	z Score†	k	x, y, z*	z Score†	k	x, y, z*	z Score†	k
Nonaversive > blank									
Dorsal medial prefrontal cortex	2, 56, 42	3.74	37	-2, 58, 28	2.94	76	-14, 60, 34	3.58	12
Visual cortex‡	2, -90, 8	5.24	13 541	-14, -86, -10	6.47	13 050	12, -86, -4	6.23	13 151
Aversive > nonaversive									
Dorsal medial prefrontal cortex	14, 44, 48	4.04	39	NSA	NSA	NSA	NSA	NSA	NSA
Dorsal anterior cingulate cortex	10, 16, 30	3.48	20	8, 24, 40	3.44	29	4, 20, 46	3.02	79
Left insula/inferior frontal gyrus	50, 16, -10	2.96	62	NSA	NSA	NSA	NSA	NSA	NSA
	-40, 20, -8	2.94	11	NSA	NSA	NSA	NSA	NSA	NSA
Amygdala/periamygdala	22, -4, -22	2.79	15	-34, -18, -16	2.79	15	NSA	NSA	NSA
Ventral medial prefrontal cortex	0, 64, 4	2.82	24	NSA	NSA	NSA	NSA	NSA	NSA

Abbreviations: k, number of contiguous voxels in cluster; NSA, no significant activation; PTSD, posttraumatic stress disorder.

\*Stereotactic coordinates from the MNI (Montreal Neurologic Institute) atlas: left/right (x), anterior/posterior (y), and superior/inferior (z), respectively.

†In a priori predicted regions, z scores listed for all foci with significance at  $P<.005$  corrected for multiple comparisons using false discovery rate in a defined volume (small-volume correction).

‡Significant activations outside of a priori search volumes ( $P<.005$ , false discovery rate corrected for multiple comparisons across the entire brain).

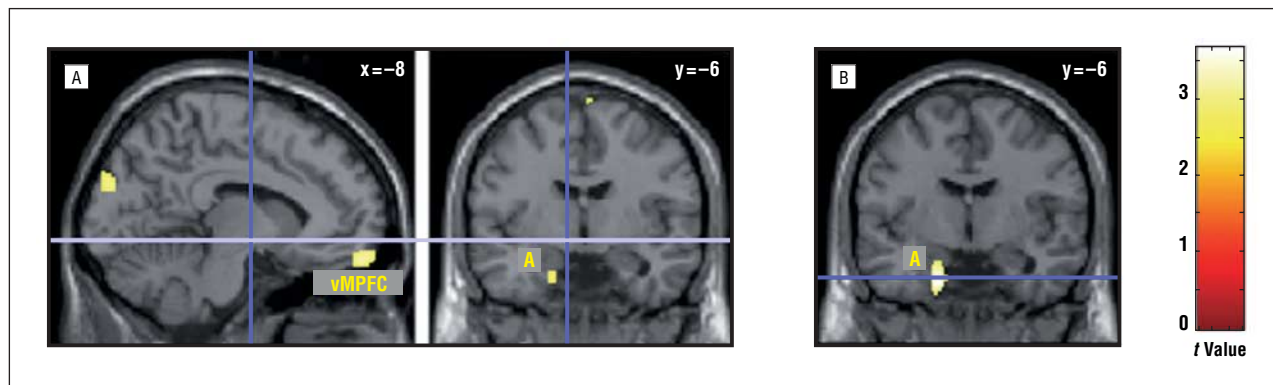
**Table 4. Areas of Greater Activation During Emotional Processing of Pictures in Controls Relative to PTSD Groups**

Aversive > Nonaversive	Normal Controls > PTSD Patients			Combat Controls > PTSD Patients		
	x, y, z*	z Score†	k	x, y, z*	z Score†	k
Ventral medial prefrontal cortex	-10, 60, -20	2.97	121	NSA	NSA	NSA
Amygdala/periamygdala	-16, -6, -28	2.72	7	-18, -8, -32	3.27	140

Abbreviations: k, number of contiguous voxels in cluster; NSA, no significant activation; PTSD, posttraumatic stress disorder.

\*Stereotactic coordinates from the MNI (Montreal Neurologic Institute) atlas: left/right (x), anterior/posterior (y), and superior/inferior (z), respectively.

†In a priori predicted regions, z scores listed for all foci with significance at  $P<.005$  corrected for multiple comparisons using false discovery rate in a defined volume (small-volume correction).



**Figure.** Statistical parametric brain activation *t* map of the regional cerebral blood flow response to emotionally negative pictures showing activation in the ventral medial prefrontal cortex (vMPFC) and amygdala (A) greater in normal controls than in posttraumatic stress disorder (PTSD) patients (A) and activation in the amygdala (A) greater in combat controls than in PTSD patients (B). Regional cerebral blood flow data are projected onto a canonical Montreal Neurologic Institute brain.

### AMYGDALA

In the nonaversive vs blank comparison, no activations or deactivations in the amygdala (eg, decreased rCBF) were noted in any group; there were no between-group differences. In the aversive vs nonaversive comparison, greater amygdalar rCBF response to aversive pictures was observed in NCs and CCs but not in PTSD patients (Table 3). In between-group comparisons, NCs and CCs had greater activation of the left amygdala to aversive pictures than the PTSD group (Table 4 and **Figure**). In the aversive vs blank comparison, NCs also had greater activation of the left amygdala ( $[-28, 0, -26]$ ;  $z=3.00$ ;  $k=30$ ) than the PTSD group. Similarly, CCs had greater amygdala activation ( $[-22, 0, -16]$ ;  $z=2.92$ ;  $k=100$ ) than the PTSD patients. Both group differences (NC>PTSD and CC>PTSD) were contributed to by increased (eg, higher) activity in the control groups and the absence of response (rather than deactivation) in the PTSD group.

### VENTRAL MPFC/OPFC

In the nonaversive vs blank comparison, neither activations nor deactivations were noted in the ventral MPFC/OPFC in any group. In the aversive vs nonaversive comparison, NCs activated the ventral MPFC, but trauma-exposed groups showed no activations in this region (Table 3). In the PTSD group, significant deactivations were observed in the ventral MPFC ( $[-10, 64, -16]$ ;  $z=3.47$ ;  $k=188$ ). Consequently, NCs had greater activation of the ventral MPFC than the PTSD group due to activation in the NCs and deactivation in the PTSD patients (Table 4 and **Figure**). No differences between trauma-exposed groups were detected.

### DORSAL ACC

In the nonaversive vs blank comparison, neither activations nor deactivations of the ACC were noted in any group. Between-group differences were not significant. In the aversive vs nonaversive comparison, all 3 groups activated the right dorsal ACC (Table 3). No between-group differences were noted.

### DORSAL MPFC

In the nonaversive vs blank comparison, all 3 groups activated dorsal MPFC (Table 3). No differences between groups were detected. In the aversive vs nonaversive comparison, only NCs activated the dorsal MPFC, but no between-group differences were detected.

### INSULA

In the nonaversive vs blank comparison, only CCs activated the insula, but no between-group differences were detected (Table 3). In the aversive vs nonaversive comparison, only NCs activated the bilateral insula, but no between-group differences were detected (Table 3).

### CLINICAL SYMPTOMS AND BRAIN ACTIVATION

No significant correlations were detected between brain activation to aversive pictures in the PTSD group and Clinician-Administered Posttraumatic Stress Disorder Scale, Toronto Alexithymia Scale, or Beck Depression Inventory scores. However, the absence of a significant finding may be due to a type II error related to the current sample size.

### INTERREGIONAL CORRELATION ANALYSES WITH THE LEFT AMYGDALA

In relation to the left amygdala, negative correlations were observed only in the dorsal ACC for all 3 groups (NCs:  $[2, 8, 36]$ ;  $z=3.57$ ; CCs:  $[0, 26, 20]$ ;  $z=3.33$ ; and PTSD patients:  $[-8, 20, 28]$ ;  $z=3.64$ ). Positive correlations were observed in the MPFC in the control groups (ventral MPFC—NCs:  $[-4, 66, 18]$ ;  $z=4.19$ ; CCs:  $[-2, 62, -18]$ ,  $z=3.44$ ; and dorsal MPFC—NCs:  $[4, 26, 66]$ ;  $z=3.65$ ; CCs:  $[-2, 42, 56]$ ;  $z=3.86$ ). However, given the post hoc nature of these interregional correlation analyses and the temporal resolution of the PET technique, we caution against conclusive interpretations of causal or reciprocal relationships.

This PET activation study examined the neural correlates of processing emotionally salient stimuli unrelated to personal traumatic experience in PTSD and observed differential corticolimbic responses in the 3 groups studied. Both NCs and CCs activated the amygdala in response to aversive stimuli, whereas the PTSD group did not show a response in this region; this difference was statistically significant in group comparisons (NC>PTSD and CC>PTSD). During negative emotional experiences, NCs also activated ventral frontal regions (ventral MPFC/OPFC), whereas both combat-exposed groups exhibited either no response (CCs) or deactivation (PTSD patients); the difference between NCs and PTSD patients was statistically significant. Unlike NCs, the combat-exposed groups showed no insular response to aversive pictures. All 3 groups activated regions within the dorsal medial frontal cortex (dorsal ACC or dorsal MPFC) to aversive and nonaversive pictures; however, only NCs activated the dorsal MPFC to negatively valenced pictures. Collectively, these findings highlight differential neural responses in the limbic (eg, amygdala) and paralimbic prefrontal cortex (ventral MPFC) to general affective experience in PTSD.

#### AMYGDALA

Our results suggest altered activity in the amygdala in response to trauma-unrelated emotional stimuli in PTSD. Animal, human lesion, and functional imaging studies suggest that the amygdala has a critical role in emotion,<sup>18,45-47</sup> in detecting fear-related cues and fear conditioning,<sup>15,18,48,49</sup> and in perceiving salience or general vigilance.<sup>27,31,50</sup> Accordingly, both non-PTSD groups (CCs and NCs) activated the amygdala during exposure to emotionally aversive stimuli. Although PTSD patients reported a negative subjective experience while viewing these pictures, they did not mount a similar increase in amygdalar activity. Our findings contrast with those of Rauch et al<sup>19</sup> and Shin et al,<sup>20</sup> who demonstrated an exaggerated response in PTSD patients to masked and overtly presented fearful faces, respectively. One potential explanation for this discrepancy is that the aversive pictures may not specifically evoke fear but rather a more general negative emotional state.<sup>18,51</sup> Furthermore, the aversive stimuli did not contain material that was personally relevant to the PTSD group, and some studies,<sup>7,8,10,52</sup> but not others,<sup>2</sup> have suggested that amygdala activation in PTSD is reserved for trauma-specific content. Alternatively, this finding could reflect the emotional flattening observed in PTSD patients, who often recognize that they do not respond affectively to emotional situations. Behavioral evidence suggests that the subjective experience of PTSD patients to aversive pictures is similar to that of controls,<sup>53,54</sup> and neuropsychologic studies suggest that the amygdala is critical not for recognition or identification of the emotional value but rather for mounting appropriate psychophysiologic responses.<sup>55</sup> Thus, the preserved subjective response and the lack of amygdalar response in our patients are con-

sistent with the emotional numbing interpretation and may reflect the chronic emotional numbing observed in PTSD patients. However, because our study did not use positive-valence stimuli, the emotional numbing interpretation is necessarily preliminary.

Task instructions could affect activations in the limbic (eg, amygdala) and prefrontal cortex regions. Recent imaging studies<sup>34,56-58</sup> have shown that when healthy volunteers label their emotions while viewing emotionally salient stimuli, amygdala activation is attenuated, whereas medial and lateral frontal cortex activity is enhanced. Although this may have affected the activation pattern, all 3 groups performed a similar task, and both control groups activated all relevant regions, including the amygdala and medial prefrontal regions, to emotional stimuli. If the absence of amygdala activations in PTSD patients is task dependent, future studies should specifically investigate the effect of cognitive-emotion interactions on corticolimbic brain activity during emotion processing in PTSD.<sup>20,42</sup>

#### VENTRAL MPFC

Neither combat-exposed group exhibited ventral MPFC activation to aversive pictures. The NCs activated ventral prefrontal regions, whereas PTSD patients had deactivation in this area, suggesting ventral MPFC hypoactivity. This deactivation to affective salience may be PTSD specific, which is consistent with reported absent or decreased MPFC activity in PTSD patients engaged in recall and imagery of personal trauma.<sup>9,12,13</sup> Current observation further extends the evidence of diminished MPFC activation in PTSD beyond traumatic reexperiencing or symptom generation and suggests the potential presence of a more generalized hypofunction. This interpretation is consistent with findings of greater rCBF decreases in the ventral MPFC in PTSD patients during emotional words retrieval.<sup>22</sup> Ventral MPFC deactivations have been associated with enhanced self-referential processing.<sup>59</sup> The MPFC is hypothesized to be involved in reexperiencing the “feelings” of one’s emotional past,<sup>60</sup> in emotional awareness,<sup>61</sup> and in reflecting on one’s own emotions/feelings.<sup>62</sup> Furthermore, an appropriate stress response seems to depend on the functional integrity of the MPFC<sup>63,64</sup> and of the medial prefrontal-amygdalar pathway.<sup>65,66</sup> The MPFC mediates the inhibition of conditioned fear after extinction,<sup>67,68</sup> and lesions to this area interfere with fear extinction<sup>69</sup> and impair emotional regulation and social interactions.<sup>70</sup> An attenuated MPFC response to negative-valenced stimuli has been described in alexithymia,<sup>71</sup> and “affect instability” has also been associated with reduced ventral MPFC function.<sup>72-74</sup> Based on these converging observations, it is plausible that MPFC hypofunction may be specifically related to the difficulties that PTSD patients have in exhibiting appropriate emotional reactivity, extinguishing fear, or mounting an appropriate stress response.

Combat controls did not activate or deactivate ventral MPFC to emotional stimuli. Although group differences were not noted between control groups or between CCs and PTSD patients, this response might be related, at least partially, to a compensatory mechanism or an adaptation to trauma exposure not related to PTSD

pathogenesis. A positive interregional rCBF correlation between the ventral MPFC and the left amygdala was observed only in CCs and NCs. Prefrontal activity may be functionally linked to amygdaloid activity,<sup>33,34,65,66</sup> and effective coupling of PFC-amygdala function could serve to regulate negative emotions and as a buffer against psychiatric disorders.<sup>58,75-80</sup> At present, the evidence regarding alterations in amygdala-MPFC coupling in PTSD is mixed. Shin and colleagues<sup>20,42</sup> reported that amygdalar responses are inversely related to those of the MPFC in PTSD patients using a similar analytic approach in 2 separate studies, whereas Gilboa and colleagues<sup>43</sup> found a positive relationship between the amygdala and the ventral MPFC (using a partial least squares “functional connectivity” approach). The lack of detectable group differences in the ventral MPFC warrants caution against the specificity that the ventral MPFC serves an adaptive compensatory function in CCs; however, the finding prompts further investigation of the complex relationship between the PFC and the amygdala as neural markers of resilience to psychiatric disease after stress.

### DORSAL MPFC AND DORSAL ACC

All the groups activated the dorsal ACC in response to emotionally salient pictures; however, only NCs mounted a dorsal MPFC response to aversive pictures. The left amygdala rCBF was negatively correlated with the dorsal ACC rCBF in all 3 groups. We also observed a positive correlation between left amygdala activity and that of the dorsal MPFC in both control groups but not in PTSD patients. Although group differences in the dorsal frontal cortex were not detected, this may be a result of individual variability of response in this region to the negatively valenced pictures, and the present study may not have had adequate power to detect a small difference. These findings are not entirely consistent with previous evidence suggesting that dorsal portions of the ACC and MPFC may be hypofunctioning in PTSD, leading to diminished cognitive function or affective regulation during emotional processing. For example, Shin and colleagues<sup>20</sup> reported less ACC recruitment during the emotional counting Stroop task in combat-related PTSD<sup>21</sup> and diminished ACC activity in response to overtly presented fearful faces. Furthermore, Lanius and colleagues<sup>12,13</sup> demonstrated failure to activate the ACC and the dorsal MPFC during the recall and imagery of personal traumatic memories. Reduced pregenual and dorsal ACC volumes<sup>81,82</sup> and decreased neuronal integrity (as indexed by *N*-acetylaspartate) in the ACC have been observed in PTSD.<sup>83</sup> These observations raise the notion that alterations in these regions may explain some deficits in cognitive functioning during emotional processing observed in PTSD patients and may be specific to PTSD. Such an interpretation is supported by animal, human lesion, and functional imaging studies, which collectively implicate dorsal frontal regions in affective regulation,<sup>17,18,34,76,84-86</sup> including the cognitive control of negative emotional experience<sup>76,77,86-88</sup> and cognitive-emotion interactions.<sup>29,34,89,90</sup> The potential functional consequences of differences in dorsal frontal cortical activity during emotion regulation in PTSD await further investigation.

### STUDY LIMITATIONS

Several limitations of this study are worth mentioning. First, the inclusion of PTSD patients with a history of comorbid conditions (eg, depression or substance abuse) and the exclusion of current active comorbid Axis I disorders are strengths and limitations. On the one hand, their inclusion matches better the representative, realistic combat veteran population; however, comorbid mood disorder and substance abuse, whether remote or current, opens the possibility that these psychiatric disorders contributed to the obtained results. However, previous psychiatric comorbidity was comparable among the groups. Similarly, because the traumatic event occurred several decades before this study, chronicity may have been a contributing factor. Also, only male combat veterans with PTSD were studied; therefore, the results do not necessarily generalize to civilian PTSD (eg, abuse, assault, and disasters) or to women. In addition, only aversive/negatively valenced stimuli were used, and future studies are needed to characterize brain activation to positive stimuli. In a cross-sectional study, it also cannot be determined whether the altered brain activation patterns preceded or followed traumatic exposure. However, the inclusion of healthy controls without previous trauma and combat-exposed individuals without PTSD allows examination of the impact of traumatic experience on brain activity. Last, aversive visual stimuli depicting dead bodies/physical wounds, although few in number, may have reminded combat-exposed individuals of their traumatic experience. All the individuals, however, were debriefed after PET, and none reported that the stimuli reminded them of their personal combat experience.

### CONCLUSIONS

In conclusion, the present study investigated the neural basis of general affective experience in PTSD. By studying controls with and without previous traumatic exposure compared with PTSD patients, we can start differentiating trauma- and PTSD-specific brain activation changes. Ventral MPFC and amygdala hypoactivity to emotional pictures seems to be specifically related to PTSD. These findings prompt future neuroimaging studies to study general emotional processing and the relationship between prefrontal cortical regions and the amygdala to deepen our understanding of the neural circuitry in PTSD.

**Submitted for Publication:** July 9, 2004; final revision received June 14, 2005; accepted July 7, 2005.

**Correspondence:** Israel Liberzon, MD, Department of Psychiatry, University of Michigan Medical School, 9D University Hospital, Box 0118, 1500 E Medical Center Dr, Ann Arbor, MI 48109-0118 (liberzon@umich.edu).

**Funding/Support:** This study was supported by a Traumatic Stress Initiative Merit Award from the Department of Veterans Affairs and the Department of Defense (Drs Liberzon and Fig) and by the Ann Arbor Veterans Affairs Health System.

**Previous Presentation:** This work was presented in part at the Society for Biological Psychiatry annual meeting; May 16, 2002; Philadelphia, Pa.

1. First MB, Spitzer RL, Williams JBW, Gibbon M. *Structured Clinical Interview for DSM-IV—Patient Edition (SCID-P)*. Washington, DC: American Psychiatric Press; 1995.
2. Liberzon I, Phan KL. Brain-imaging studies of posttraumatic stress disorder. *CNS Spectr*. 2003;8:641-650.
3. Hull AM. Neuroimaging findings in post-traumatic stress disorder: systematic review. *Br J Psychiatry*. 2002;181:102-110.
4. Pitman RK, Shin LM, Rauch SL. Investigating the pathogenesis of posttraumatic stress disorder with neuroimaging. *J Clin Psychiatry*. 2001;62(suppl 17):47-54.
5. Bremner JD. Neuroimaging studies in post-traumatic stress disorder. *Curr Psychiatry Rep*. 2002;4:254-263.
6. Rauch SL, Shin LM, Wright CI. Neuroimaging studies of amygdala function in anxiety disorders. *Ann N Y Acad Sci*. 2003;985:389-410.
7. Liberzon I, Taylor SF, Amdur R, Jung TD, Chamberlain KR, Minoshima S, Koeppe RA, Fig LM. Brain activation in PTSD in response to trauma-related stimuli. *Biol Psychiatry*. 1999;45:817-826.
8. Pissiota A, Frans O, Fernandez M, von Knorring L, Fischer H, Fredrikson M. Neurofunctional correlates of posttraumatic stress disorder: a PET symptom provocation study. *Eur Arch Psychiatry Clin Neurosci*. 2002;252:68-75.
9. Bremner JD, Staib LH, Kaloupek D, Southwick SM, Soufer R, Charney DS. Neural correlates of exposure to traumatic pictures and sound in Vietnam combat veterans with and without posttraumatic stress disorder: a positron emission tomography study. *Biol Psychiatry*. 1999;45:806-816.
10. Rauch SL, van der Kolk BA, Filsler RE, Alpert NM, Orr SP, Savage CR, Fischman AJ, Jenike MA, Pitman RK. A symptom provocation study of posttraumatic stress disorder using positron emission tomography and script-driven imagery. *Arch Gen Psychiatry*. 1996;53:380-387.
11. Shin LM, McNally RJ, Kosslyn SM, Thompson WL, Rauch SL, Alpert NM, Metzger LJ, Lasko NB, Orr SP, Pitman RK. Regional cerebral blood flow during script-driven imagery in childhood sexual abuse-related PTSD: a PET investigation. *Am J Psychiatry*. 1999;156:575-584.
12. Lanius RA, Williamson PC, Boksman K, Densmore M, Gupta M, Neufeld RW, Gati JS, Menon RS. Brain activation during script-driven imagery induced dissociative responses in PTSD: a functional magnetic resonance imaging investigation. *Biol Psychiatry*. 2002;52:305-311.
13. Lanius RA, Williamson PC, Densmore M, Boksman K, Gupta MA, Neufeld RW, Gati JS, Menon RS. Neural correlates of traumatic memories in posttraumatic stress disorder: a functional MRI investigation. *Am J Psychiatry*. 2001;158:1920-1922.
14. Bremner JD, Narayan M, Staib LH, Southwick SM, McGlashan T, Charney DS. Neural correlates of memories of childhood sexual abuse in women with and without posttraumatic stress disorder. *Am J Psychiatry*. 1999;156:1787-1795.
15. LeDoux JE. Emotion circuits in the brain. *Annu Rev Neurosci*. 2000;23:155-184.
16. Bechara A, Damasio H, Damasio AR. Emotion, decision making and the orbitofrontal cortex. *Cereb Cortex*. 2000;10:295-307.
17. Davidson RJ, Irwin W. The functional neuroanatomy of emotion and affective style. *Trends Cogn Sci*. 1999;3:11-21.
18. Phan KL, Wager T, Taylor SF, Liberzon I. Functional neuroanatomy of emotion: a meta-analysis of emotion activation studies in PET and fMRI. *Neuroimage*. 2002;16:331-348.
19. Rauch SL, Whalen PJ, Shin LM, McInerney SC, Macklin ML, Lasko NB, Orr SP, Pitman RK. Exaggerated amygdala response to masked facial stimuli in posttraumatic stress disorder: a functional MRI study. *Biol Psychiatry*. 2000;47:769-776.
20. Shin LM, Wright CI, Cannistraro PA, Wedig MM, McMullin K, Martis B, Macklin ML, Lasko NB, Cavanagh SR, Krangel TS, Orr SP, Pitman RK, Whalen PJ, Rauch SL. A functional magnetic resonance imaging study of amygdala and medial prefrontal cortex responses to overtly presented fearful faces in posttraumatic stress disorder. *Arch Gen Psychiatry*. 2005;62:273-281.
21. Shin LM, Whalen PJ, Pitman RK, Bush G, Macklin ML, Lasko NB, Orr SP, McInerney SC, Rauch SL. An fMRI study of anterior cingulate function in posttraumatic stress disorder. *Biol Psychiatry*. 2001;50:932-942.
22. Bremner JD, Vythilingam M, Vermetten E, Southwick SM, McGlashan T, Staib LH, Soufer R, Charney DS. Neural correlates of declarative memory for emotionally valenced words in women with posttraumatic stress disorder related to early childhood sexual abuse. *Biol Psychiatry*. 2003;53:879-889.
23. Lanius RA, Williamson PC, Hopper J, Densmore M, Boksman K, Gupta MA, Neufeld RW, Gati JS, Menon RS. Recall of emotional states in posttraumatic stress disorder: an fMRI investigation. *Biol Psychiatry*. 2003;53:204-210.
24. Lang PJ, Bradley MM, Cuthbert BN. *International Affective Picture System (IAPS): Technical Manual and Affective Ratings*. Gainesville: NIMH Center for the Study of Emotion and Attention, University of Florida; 1997.
25. Lang PJ, Greenwald MK, Bradley MM, Hamm AO. Looking at pictures: affective, facial, visceral, and behavioral reactions. *Psychophysiology*. 1993;30:261-273.
26. Taylor SF, Liberzon I, Koeppe RA. The effect of graded aversive stimuli on limbic and visual activation. *Neuropsychologia*. 2000;38:1415-1425.
27. Liberzon I, Phan KL, Decker LR, Taylor SF. Extended amygdala and emotional salience: a PET activation study of positive and negative affect. *Neuropsychopharmacology*. 2003;28:726-733.
28. Phan KL, Taylor SF, Welsh RC, Decker LR, Noll DC, Nichols TE, Britton JC, Liberzon I. Activation of the medial prefrontal cortex and extended amygdala by individual ratings of emotional arousal: a functional magnetic resonance imaging study. *Biol Psychiatry*. 2003;53:211-215.
29. Simpson JR, Ongur D, Akbudak E, Conturo TE, Ollinger JM, Snyder AZ, Gusnard DA, Raichle ME. The emotional modulation of cognitive processing: an fMRI study. *J Cogn Neurosci*. 2000;12(suppl 2):157-170.
30. Lane RD, Fink GR, Chau PM, Dolan RJ. Neural activation during selective attention to subjective emotional responses. *Neuroreport*. 1997;8:3969-3972.
31. Hamann SB, Ely TD, Hoffman JM, Kilts CD. Ecstasy and agony: activation of the human amygdala in positive and negative emotion. *Psychol Sci*. 2002;13:135-141.
32. First MB Sr, Gibbon M, Williams JBW. *Structured Clinical Interview for DSM-IV Axis I Disorders (SCID)*. New York, NY: Psychiatric Institute, Biometrics Research; 1997.
33. Liberzon I, Zubieta JK, Fig LM, Phan KL, Koeppe RA, Taylor SF.  $\mu$ -Opioid receptors and limbic responses to aversive emotional stimuli. *Proc Natl Acad Sci U S A*. 2002;99:7084-7089.
34. Taylor SF, Phan KL, Decker LR, Liberzon I. Subjective rating of emotionally salient stimuli modulates neural activity. *Neuroimage*. 2003;18:650-659.
35. Britton JC, Phan KL, Taylor SF, Fig LM, Liberzon I. Corticolimbic blood flow in posttraumatic stress disorder during script-driven imagery. *Biol Psychiatry*. 2005;57:832-840.
36. Friston KJ, Frith CD, Liddle PF, Frackowiak RS. Comparing functional (PET) images: the assessment of significant change. *J Cereb Blood Flow Metab*. 1991;11:690-699.
37. Friston KJ, Holmes AP, Worsley KJ, Poline JB, Frith CD, Frackowiak RS. Statistical parametric maps in functional imaging: a general linear approach. *Hum Brain Mapp*. 1995;2:189-210.
38. Ashburner J, Neelin P, Collins DL, Evans A, Friston K. Incorporating prior knowledge into image registration. *Neuroimage*. 1997;6:344-352.
39. Ashburner J, Andersson JL, Friston KJ. High-dimensional image registration using symmetric priors. *Neuroimage*. 1999;9:619-628.
40. Holmes AP, Friston KJ. Generalisability, random effects and population inference [abstract]. *Neuroimage*. 1998;7:S754.
41. Genovese CR, Lazar NA, Nichols T. Thresholding of statistical maps in functional neuroimaging using the false discovery rate. *Neuroimage*. 2002;15:870-878.
42. Shin LM, Orr SP, Carson MA, Rauch SL, Macklin ML, Lasko NB, Peters PM, Metzger LJ, Dougherty DD, Cannistraro PA, Alpert NM, Fischman AJ, Pitman RK. Regional cerebral blood flow in the amygdala and medial prefrontal cortex during traumatic imagery in male and female Vietnam veterans with PTSD. *Arch Gen Psychiatry*. 2004;61:168-176.
43. Gilboa A, Shalev AY, Laor L, Lester H, Louzoun Y, Chisin R, Bonne O. Functional connectivity of the prefrontal cortex and the amygdala in posttraumatic stress disorder. *Biol Psychiatry*. 2004;55:263-272.
44. Friston KJ, Buechel C, Fink GR, Morris J, Rolls E, Dolan RJ. Psychophysiological and modulatory interactions in neuroimaging. *Neuroimage*. 1997;6:218-229.
45. LeDoux JE. *The Emotional Brain*. New York, NY: Touchstone; 1996.
46. Adolphs R, Tranel D, Hamann S, Young AW, Calder AJ, Phelps EA, Anderson A, Lee GP, Damasio AR. Recognition of facial emotion in nine individuals with bilateral amygdala damage. *Neuropsychologia*. 1999;37:1111-1117.
47. Anderson AK, Phelps EA. Lesions of the human amygdala impair enhanced perception of emotionally salient events. *Nature*. 2001;411:305-309.
48. Adolphs R, Tranel D, Damasio H, Damasio AR. Fear and the human amygdala. *J Neurosci*. 1995;15:5879-5891.
49. Buchel C, Dolan RJ. Classical fear conditioning in functional neuroimaging. *Curr Opin Neurobiol*. 2000;10:219-223.
50. Davis M, Whalen PJ. The amygdala: vigilance and emotion. *Mol Psychiatry*. 2001;6:13-34.
51. Phan KL, Wager TD, Taylor SF, Liberzon I. Functional neuroimaging studies of human emotions. *CNS Spectr*. 2004;9:258-266.
52. Shin LM, Kosslyn SM, McNally RJ, Alpert NM, Thompson WL, Rauch SL, Macklin ML, Pitman RK. Visual imagery and perception in posttraumatic stress disorder: a positron emission tomographic investigation. *Arch Gen Psychiatry*. 1997;54:233-241.
53. Amdur RL, Larsen R, Liberzon I. Emotional processing in combat-related posttraumatic stress disorder: a comparison with traumatized and normal controls. *J Anxiety Disord*. 2000;14:219-238.
54. Litz BT, Orsillo SM, Kaloupek D, Weathers F. Emotional processing in posttraumatic stress disorder. *J Abnorm Psychol*. 2000;109:26-39.



55. Bechara A, Damasio H, Damasio AR. Role of the amygdala in decision-making. *Ann N Y Acad Sci*. 2003;985:356-369.
56. Lange K, Williams LM, Young AW, Bullmore ET, Brammer MJ, Williams SC, Gray JA, Phillips ML. Task instructions modulate neural responses to fearful facial expressions. *Biol Psychiatry*. 2003;53:226-232.
57. Hariri AR, Bookheimer SY, Mazziotta JC. Modulating emotional responses: effects of a neocortical network on the limbic system. *Neuroreport*. 2000;11:43-48.
58. Keightley ML, Winocur G, Graham SJ, Mayberg HS, Hevenor SJ, Grady CL. An fMRI study investigating cognitive modulation of brain regions associated with emotional processing of visual stimuli. *Neuropsychologia*. 2003;41:585-596.
59. Gusnard DA, Akbudak E, Shulman GL, Raichle ME. Medial prefrontal cortex and self-referential mental activity: relation to a default mode of brain function. *Proc Natl Acad Sci U S A*. 2001;98:4259-4264.
60. Damasio AR. *The Feeling of What Happens: Body and Emotion in the Making of Consciousness*. New York, NY: Harcourt Brace; 1999.
61. Lane RD, Reiman EM, Ahern GL, Schwartz GE, Davidson RJ. Neuroanatomical correlates of happiness, sadness, and disgust. *Am J Psychiatry*. 1997;154:926-933.
62. Ochsner KN, Knierim K, Ludlow DH, Hanelin J, Ramachandran T, Glover G, Mackey SC. Reflecting upon feelings: an fMRI study of neural systems supporting the attribution of emotion to self and other. *J Cogn Neurosci*. 2004;16:1746-1772.
63. Figueiredo HF, Bruestle A, Bodie B, Dolgas CM, Herman JP. The medial prefrontal cortex differentially regulates stress-induced c-fos expression in the fore-brain depending on type of stressor. *Eur J Neurosci*. 2003;18:2357-2364.
64. Bremner JD. Functional neuroanatomical correlates of traumatic stress revisited 7 years later, this time with data. *Psychopharmacol Bull*. 2003;37:6-25.
65. Maroun M, Richter-Levin G. Exposure to acute stress blocks the induction of long-term potentiation of the amygdala-prefrontal cortex pathway in vivo. *J Neurosci*. 2003;23:4406-4409.
66. Rosenkranz JA, Moore H, Grace AA. The prefrontal cortex regulates lateral amygdala neuronal plasticity and responses to previously conditioned stimuli. *J Neurosci*. 2003;23:11054-11064.
67. Milad MR, Quirk GJ. Neurons in medial prefrontal cortex signal memory for fear extinction. *Nature*. 2002;420:70-74.
68. Quirk GJ, Likhtik E, Pelletier JG, Pare D. Stimulation of medial prefrontal cortex decreases the responsiveness of central amygdala output neurons. *J Neurosci*. 2003;23:8800-8807.
69. Morgan MA, Romanski LM, LeDoux JE. Extinction of emotional learning: contribution of medial prefrontal cortex. *Neurosci Lett*. 1993;163:109-113.
70. Damasio AR. *Descartes' Error*. New York, NY: Avon Books Inc; 1994.
71. Berthoz S, Artiges E, Van De Moortele PF, Poline JB, Rouquette S, Comolli SM, Martinot JL. Effect of impaired recognition and expression of emotions on frontocingulate cortices: an fMRI study of men with alexithymia. *Am J Psychiatry*. 2002;159:961-967.
72. New AS, Hazlett EA, Buchsbaum MS, Goodman M, Reynolds D, Mitropoulou V, Sprung L, Shaw RB Jr, Koenigsberg H, Platholi J, Silverman J, Siever LJ. Blunted prefrontal cortical <sup>18</sup>F-fluorodeoxyglucose positron emission tomography response to meta-chlorophenylpiperazine in impulsive aggression. *Arch Gen Psychiatry*. 2002;59:621-629.
73. Blumberg HP, Leung HC, Skudlarski P, Lacadie CM, Fredericks CA, Harris BC, Charney DS, Gore JC, Krystal JH, Peterson BS. A functional magnetic resonance imaging study of bipolar disorder: state- and trait-related dysfunction in ventral prefrontal cortices. *Arch Gen Psychiatry*. 2003;60:601-609.
74. Dougherty DD, Rauch SL, Deckersbach T, Marci C, Loh R, Shin LM, Alpert NM, Fischman AJ, Fava M. Ventromedial prefrontal cortex and amygdala dysfunction during an anger induction positron emission tomography study in patients with major depressive disorder with anger attacks. *Arch Gen Psychiatry*. 2004;61:795-804.
75. Ochsner KN, Gross JJ. The cognitive control of emotion. *Trends Cogn Sci*. 2005;9:242-249.
76. Ochsner KN, Bunge SA, Gross JJ, Gabrieli JD. Rethinking feelings: an fMRI study of the cognitive regulation of emotion. *J Cogn Neurosci*. 2002;14:1215-1229.
77. Phan KL, Fitzgerald DA, Nathan PJ, Moore GJ, Uhdé TW, Tancer ME. Neural substrates for voluntary suppression of negative affect: a functional magnetic resonance imaging study. *Biol Psychiatry*. 2005;57:210-219.
78. Pezawas L, Meyer-Lindenberg A, Drabant EM, Verchinski BA, Munoz KE, Kolachana BS, Egan MF, Mattay VS, Hariri AR, Weinberger DR. 5-HTTLPR polymorphism impacts human cingulate-amygdala interactions: a genetic susceptibility mechanism for depression. *Nat Neurosci*. 2005;8:828-834.
79. Heinz A, Braus DF, Smolka MN, Wrase J, Puls I, Hermann D, Klein J, Grusser SM, Flor H, Schumann G, Mann K, Buchel C. Amygdala-prefrontal coupling depends on a genetic variation of the serotonin transporter. *Nat Neurosci*. 2005;8:20-21 S.
80. Mayberg HS. Modulating limbic-cortical circuits in depression: targets of antidepressant treatments. *Semin Clin Neuropsychiatry*. 2002;7:255-268.
81. Rauch SL, Shin LM, Segal E, Pitman RK, Carson MA, McMullin K, Whalen PJ, Makris N. Selectively reduced regional cortical volumes in post-traumatic stress disorder. *Neuroreport*. 2003;14:913-916.
82. Yamasue H, Kasai K, Iwanami A, Yamada H, Abe O, Kuroki N, Fukuda R, Tochigi M, Furukawa S, Sadamatsu M, Sasaki T, Aoki S, Ohtomo K, Asukai N, Kato N. Voxel-based analysis of MRI reveals anterior cingulate gray-matter volume reduction in posttraumatic stress disorder due to terrorism. *Proc Natl Acad Sci U S A*. 2003;100:9039-9043.
83. De Bellis MD, Keshavan MS, Spencer S, Hall J. N-Acetylaspartate concentration in the anterior cingulate of maltreated children and adolescents with PTSD. *Am J Psychiatry*. 2000;157:1175-1177.
84. Bush G, Luu P, Posner MI. Cognitive and emotional influences in anterior cingulate cortex. *Trends Cogn Sci*. 2000;4:215-222.
85. Davidson RJ, Putnam KM, Larson CL. Dysfunction in the neural circuitry of emotion regulation: a possible prelude to violence. *Science*. 2000;289:591-594.
86. Levesque J, Eugene F, Joannette Y, Paquette V, Mensour B, Beaudoin G, Leroux JM, Bourgoin P, Beauregard M. Neural circuitry underlying voluntary suppression of sadness. *Biol Psychiatry*. 2003;53:502-510.
87. Ochsner KN, Bunge SA, Gross JJ, Gabrieli JD. Rethinking feelings: an fMRI study of cognitive regulation of emotion. *J Cogn Neurosci*. 2002;14:1215-1229.
88. Beauregard M, Levesque J, Bourgoin P. Neural correlates of conscious self-regulation of emotion. *J Neurosci*. 2001;21:1-6.
89. Liberzon I, Taylor SF, Fig LM, Decker LR, Koeppe RA, Minoshima S. Limbic activation and psychophysiological responses to aversive visual stimuli: interaction with cognitive task. *Neuropsychopharmacology*. 2000;23:508-516.
90. Hariri AR, Mattay VS, Tessitore A, Fera F, Weinberger DR. Neocortical modulation of the amygdala response to fearful stimuli. *Biol Psychiatry*. 2003;53:494-501.