

REVIEW ARTICLE

John A. Jarcho, M.D., *Editor*

Catheter Ablation of Ventricular Arrhythmias

Kalyanam Shivkumar, M.D., Ph.D.

VENTRICULAR TACHYCARDIA ARISES FROM AN ABNORMAL ELECTRICAL focus or circuit in the myocardium of the ventricle and is usually manifested as a tachyarrhythmia with a wide QRS complex on electrocardiography (ECG), with or without clinical consequences ranging from dizziness to syncope or sudden cardiac death. Management of ventricular tachycardia requires an assessment of the risk of sudden death posed by the arrhythmia, evaluation for the presence and extent of underlying heart disease, and weighing of the risks and benefits of available treatments.

In patients with structural heart disease, ventricular tachycardia is associated with an increased risk of sudden cardiac death.^{1,2} Implantable cardioverter–defibrillators (ICDs) have become the established means of preventing sudden death in these patients.^{1,2} However, ICDs do not prevent ventricular tachycardia. When the burden of ventricular tachycardia is high, resulting in multiple ICD shocks or antitachycardia pacing, additional treatment is required. Drug therapy for ventricular tachycardia in patients with ICDs includes beta-blockers and antiarrhythmic agents such as sotalol, mexiletine, dofetilide, and amiodarone.

For patients with ventricular tachycardia in the absence of structural heart disease, the risk of sudden death is low. Drug therapy is commonly used for symptom management in such patients, with beta-blockers and nondihydropyridine calcium-channel blockers used as first-line agents.^{1,2}

Catheter-based management of ventricular tachycardia was inspired by surgical studies, which showed that resection of myocardial scars could result in control of ventricular tachycardia.³ Successful catheter-based ablation of ventricular tachycardia was initially reported in 1983,⁴ and its use has increased in the past two decades, with the development of radiofrequency ablation in the 1990s.⁵ Catheter ablation is typically considered for the treatment of ventricular tachycardia when drugs are ineffective or have unacceptable side effects.⁶

PATHOPHYSIOLOGY

VENTRICULAR TACHYCARDIA IN THE ABSENCE OF STRUCTURAL HEART DISEASE

In a structurally normal heart, ventricular tachycardia can be idiopathic or due to genetic arrhythmia syndromes.⁷ Idiopathic ventricular tachycardias, which are the most common type, are typically monomorphic (having a single QRS pattern on ECG), indicating that they originate from a single discrete focus. The focus is most often located in the outflow region of one of the ventricles, either supra- or infravalvular, although it can be located in another ventricular myocardial location (Fig. 1).⁸ In general, idiopathic ventricular tachycardias can be ablated with limited delivery of radiofrequency energy to the site of origin of the arrhythmia. Ventricular tachycardias due to genetic arrhythmia syndromes (usually caused by disorders of ion-channel function) tend to be polymorphic on ECG (not originating from a single discrete focus) and are typically not amenable to catheter ablation.

From the University of California, Los Angeles (UCLA), Cardiac Arrhythmia Center and Electrophysiology Programs, David Geffen School of Medicine at UCLA, Los Angeles. Address reprint requests to Dr. Shivkumar at the UCLA Cardiac Arrhythmia Center, 100 UCLA Medical Plaza, Suite 660, Los Angeles, CA 90095, or at kshivkumar@mednet.ucla.edu.

N Engl J Med 2019;380:1555-64.

DOI: 10.1056/NEJMra1615244

Copyright © 2019 Massachusetts Medical Society.

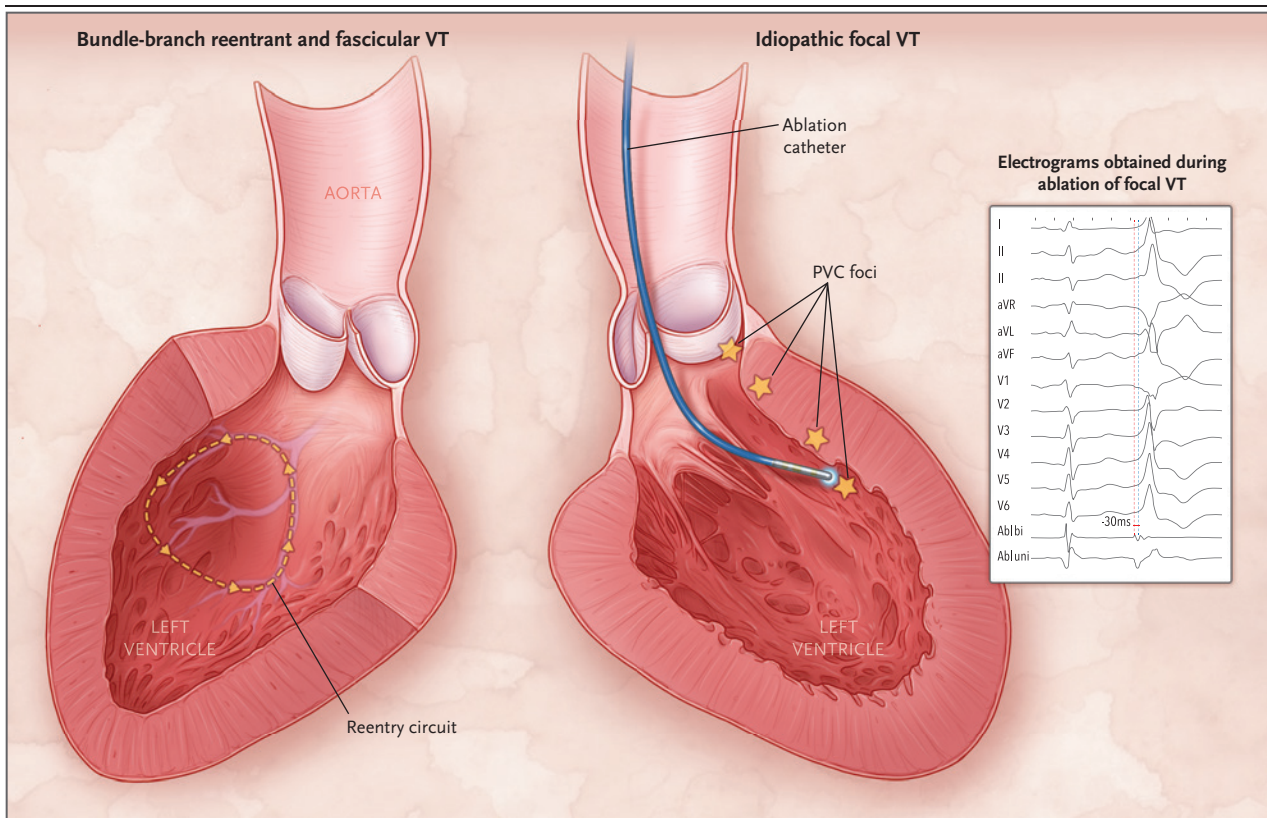


Figure 1. Mechanisms and Catheter Ablation of Ventricular Tachycardia (VT) in the Absence of Structural Heart Disease.

Shown are two views of the left ventricle and common mechanisms of VT in patients who do not have structural heart disease. In bundle-branch reentrant and fascicular VT, a reentry circuit incorporating the cardiac conduction system is present (arrows show the direction of movement of the depolarization wave). In idiopathic VT, the tachyarrhythmia typically arises from a discrete myocardial focus. At this focus, abnormal impulse formation occurs either during or after the normal cardiac action potential (i.e., the abnormal impulse triggers arrhythmia). In this example, an ablation catheter is passed in a retrograde fashion through the aortic valve into the left ventricle. During the ablation procedure, electrograms are obtained with the use of the body-surface electrocardiographic (ECG) leads, as well as recordings from the ablation catheter itself. Shown are a bipolar recording from the ablation catheter (Abl bi), in which two electrodes, positioned proximally and distally on the catheter, are used to obtain a very localized signal, and a unipolar recording (Abl uni), in which the distal electrode is used to obtain a signal between the catheter tip and a remote electrode. The electrograms document one sinus beat followed by a premature ventricular complex (PVC); the catheter recordings document an abnormal electrical potential occurring 30 msec before the body-surface complex, indicating that the catheter tip is close to the focus of initiation of the PVC.

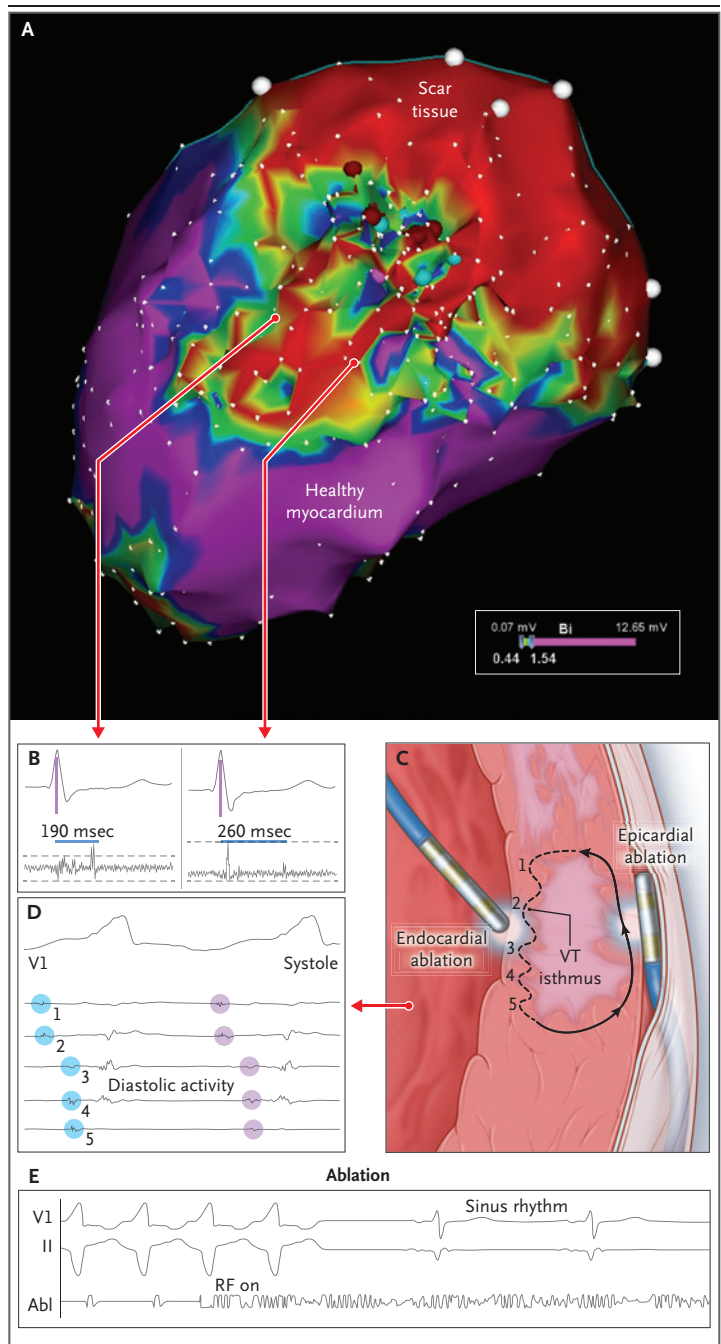
VENTRICULAR TACHYCARDIA IN THE PRESENCE OF STRUCTURAL HEART DISEASE

In the presence of structural heart disease, ventricular tachycardia is typically monomorphic and is usually due to a reentrant mechanism resulting from the formation of an abnormal electrical circuit in the myocardium. Myocardial scars from previous myocardial infarction or surgical procedures⁹ set the stage for the discontinuous propagation of myocardial electrical impulses, which results in reentry (Fig. 2).^{10,11} Catheter ablation has been used to target arrhythmogenic regions of these scars for the control of ventricular tachycardia. Myocardial scars can

also be seen in patients with nonischemic cardiomyopathy¹²; the scars in such patients tend to be diffuse or patchy and can be seen in almost any location. Other structural cardiac disorders, such as sarcoidosis¹³ and arrhythmogenic right ventricular cardiomyopathy,¹⁴ are associated with specific myocardial abnormalities that confer a predisposition to the development of scar-based ventricular tachycardia. Although the role of scar tissue is of fundamental importance in the development of ventricular tachycardia in patients with structural heart disease, additional pathophysiological factors, such as activation of the autonomic nervous system, stretching of the

Figure 2. Mechanisms and Catheter Ablation of VT in the Presence of Structural Heart Disease.

A substrate voltage map (Panel A) is used to identify areas of severely diseased myocardium and VT circuit in the region of dense myocardial scar. The voltage map is an array of measurements of local myocardial voltage obtained during sinus rhythm. The voltage level ranges from high voltage (>1.5 mV, magenta; healthy myocardium) to extremely low or no voltage (<0.5 mV, red; scar tissue). Panel B shows a surface ECG recording and electrograms recorded from ablation catheters positioned in the heart. Shown are two "late potentials" detected with the ablation catheters; the potentials are late with respect to the potential arising from the rest of the myocardium (which is simultaneous with the QRS complex in the surface ECG). Late potentials represent delayed conduction of the main cardiac depolarization wave through an area of diseased myocardium; they are indicative of an electrophysiological substrate for reentrant VT. Panel C depicts scar tissue in the myocardium and the location of a VT circuit. The arrows show the path of the circuit through the myocardium, and the dashed section of the circuit indicates slow conduction through the area of scar tissue (with numbers 1 through 5 representing five locations from which electrograms were obtained). Panel D shows two beats of VT (recordings from intracardiac catheters from five locations [numbered 1 through 5] in the VT circuit and from surface ECG lead V₁; the blue and lavender circles highlight abnormal signals recorded by the catheter). The intracardiac electrograms document a wave of depolarization occurring during diastole and sequentially passing through the electrode sites spanning the VT circuit. A repetitive pattern of sequential electrograms of this type is indicative of a reentrant circuit. Panel E shows recordings from surface ECG leads (V₁ and lead II) and an ablation catheter (Abl) recording during an episode of VT. Radiofrequency (RF) current delivery through the catheter is initiated at the point marked "RF: on" and is followed by termination of VT.



cardiac chambers, molecular changes associated with hypertrophy, and heart failure, also contribute to arrhythmogenesis.^{7,15}

MANAGEMENT

INITIAL EVALUATION

The first step in the initial management of ventricular tachycardia is an assessment of hemodynamics, and if the patient's condition is unstable, synchronized cardioversion (for monomorphic ventricular tachycardia) or defibrillation (for polymorphic ventricular tachycardia or ventricular fibrillation) should be performed immediately. When possible, a 12-lead ECG of the tachycardia and recordings of the initiation and termination

of the arrhythmia should be reviewed. Reversible causes of ventricular tachycardia, such as ischemia, electrolyte abnormalities, and drug-induced proarrhythmia, need to be considered (Table 1). Echocardiography should be performed to determine whether structural heart disease is present. Magnetic resonance imaging (MRI), coronary computed tomographic (CT) angiography, or cardiac catheterization with angiography may be

Table 1. Evaluation and Management of Ventricular Tachycardia (VT).***Preprocedure evaluation**

Review of 12-lead ECG
 Transthoracic echocardiogram
 ICD interrogation and programming
 Use of a Holter monitor or other event recorder (to assess PVC burden)
 Management of myocardial ischemia
 Management of heart failure
 Imaging (MRI) to locate scars
 FDG-PET to rule out inflammation (in appropriate cases)
 Treatment of coexisting disorders (electrolyte abnormalities, renal failure)

Management of VT storm

Care in the ICU, beta-blockade, antiarrhythmic drug therapy (amiodarone)
 Intubation, deep sedation
 Mechanical hemodynamic support (intraaortic balloon pump, LVAD)
 Neuraxial modulation: thoracic epidural anesthesia, stellate ganglion blockade
 Radiofrequency catheter ablation

* ECG denotes electrocardiogram, FDG-PET ¹⁸F-fluorodeoxyglucose–positron-emission tomography, ICD implantable cardioverter–defibrillator, ICU intensive care unit, LVAD left ventricular assist device, and PVC premature ventricular complex.

needed for select patients. Coexisting conditions, such as cardiac ischemia and heart, respiratory, or renal failure, should be actively managed.

INDICATIONS FOR CATHETER ABLATION OF VENTRICULAR TACHYCARDIA

In patients with structural heart disease, ablation is indicated for sustained monomorphic ventricular tachycardia that recurs despite treatment with antiarrhythmic drugs or if such drugs have unacceptable side effects or are not desired. In the absence of structural heart disease, catheter ablation is indicated if monomorphic ventricular tachycardia causes symptoms or antiarrhythmic drugs are ineffective. A subset of patients in whom a high burden of monomorphic premature ventricular complexes (PVCs) results in ventricular dysfunction may benefit from catheter ablation.¹⁶ PVCs can also occur in patients with structural heart disease¹⁷ and may need to be targeted to improve the efficacy of cardiac resynchronization devices.¹⁸ Very high mortality is associated with patients who have recurrent, refractory ventricular tachycardia, often termed “ventricular tachycardia storm” (three or more episodes within 24 hours), and catheter ablation of ventricular tachycardia in such patients has been shown to be effective, once the patient’s condition has been

stabilized (which may require intubation, deep sedation, and other techniques, as noted in Table 1).¹⁹ Contraindications for ablation of ventricular tachycardia include a mobile left ventricular thrombus and reversible causes of ventricular tachycardia (e.g., acute ischemia and electrolyte disturbances).

PREPROCEDURE IMAGING

Patients with coronary artery disease may require coronary angiography and functional testing to determine whether ischemia (a reversible cause of ventricular tachycardia) is present; if it is present, coronary revascularization should be considered before catheter ablation. MRI with gadolinium enhancement aids characterization of the myocardial tissue (substrate) before ablation. MRI is especially useful for identifying specific scar locations,²⁰ such as the interventricular septum²¹; scars that are deep within the myocardial wall may require specialized targeting techniques.^{22,23} In some patients (e.g., those with sarcoidosis), active myocardial inflammation may play a role in the pathogenesis of ventricular tachycardia; ¹⁸F-fluorodeoxyglucose–positron-emission tomography (FDG-PET) is useful for the assessment of ongoing inflammation.²⁴

PROCEDURAL ASPECTS OF CATHETER ABLATION**SEDATION AND ANESTHESIA**

Careful attention to the patient’s comfort and control of the airway are crucial for safe catheter ablation of ventricular tachycardia.²⁵ Most ablation procedures can be performed with the patient under light conscious sedation. For a subset of procedures, deep sedation and general anesthesia may be necessary; patients with heart failure may also require intraoperative hemodynamic management.

CATHETER TECHNOLOGY AND ACCESS

Radiofrequency catheters have an electrode designed for the delivery of alternating current in the radiofrequency wavelength range (350 to 500 kHz), which results in resistive heating and permanent tissue ablation (destruction). Irrigated catheters are designed to cool the electrode with saline²⁶; this permits greater energy transfer to the tissue, allowing larger lesion formation. Another advance in catheter technology in the past decade is “force sensing” at the catheter tip,

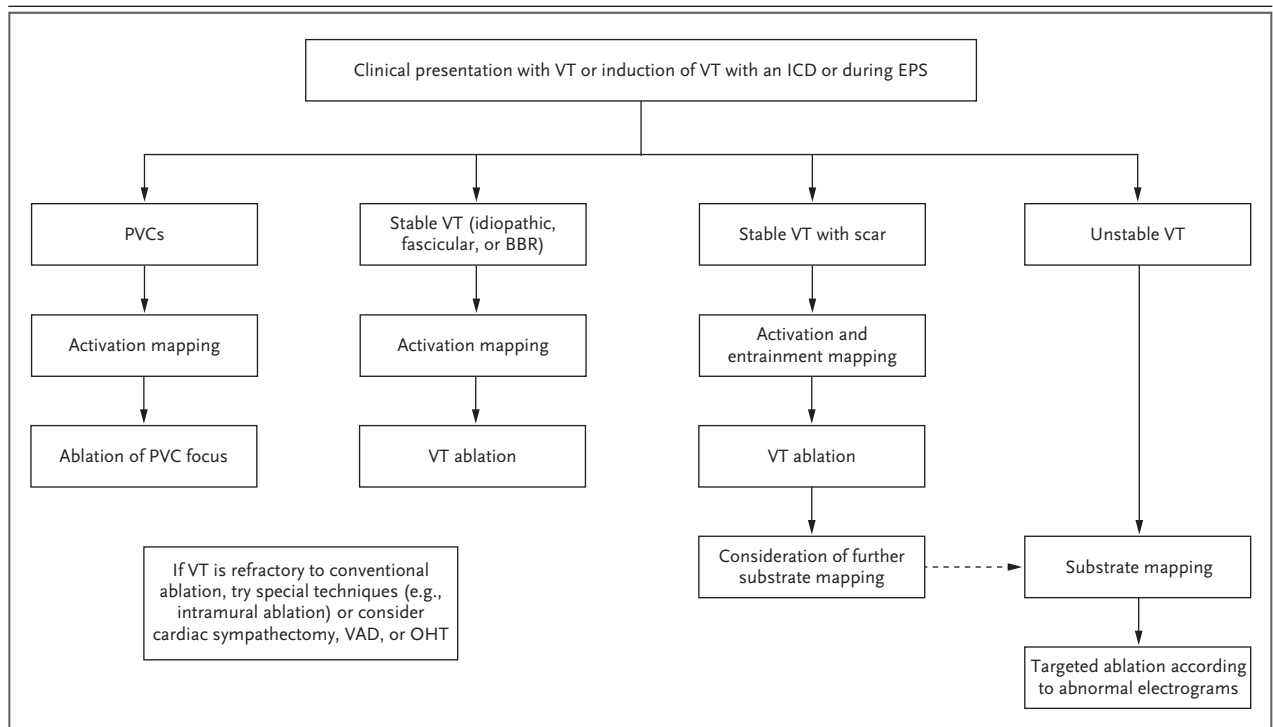


Figure 3. Strategy for Catheter Ablation of Ventricular Arrhythmias.

Shown are strategies for mapping and ablation of various types of VT. In most cases, mapping is performed either by studying spontaneously occurring VT or by inducing VT, which may be accomplished with the use of an implantable cardioverter-defibrillator (ICD), if the patient has one, or by programmed stimulation during an electrophysiological study (EPS). For patients with PVCs, activation or pace mapping may be performed, followed by ablation of the PVC focus. Stable VT in the absence of structural heart disease, including idiopathic VT, bundle-branch reentrant (BBR) VT, and fascicular VT, can typically be managed by activation mapping, followed by ablation of the VT focus or circuit. In patients with structural heart disease and scar who have stable VT, activation or entrainment mapping can be used; after ablation, further substrate mapping may be considered. Patients with unstable VT typically cannot be evaluated during the arrhythmia and must instead be evaluated during sinus rhythm or pacing; this is generally accomplished with substrate mapping and targeted ablation according to abnormal electrograms. In patients who have refractory VT, special techniques may be considered, including needle ablation, ethanol infusion, and intracoronary coil embolization. OHT denotes orthotopic heart transplantation, and VAD ventricular assist device.

which ensures adequate contact with tissue for effective radiofrequency ablation.

For ablation procedures performed in the right ventricle, femoral venous access is the conventional approach. For procedures performed in the left ventricle, access may be obtained by means of either a retrograde approach through the femoral artery and across the aortic valve or a transseptal approach across the interatrial septum. The use of separate catheters for recording, pacing, and ablation may require multiple vascular-access sites.

PRINCIPLES OF MAPPING AND ABLATION

A 12-lead ECG obtained during an episode of monomorphic ventricular tachycardia can indicate the likely site of origin of the arrhythmia

and is therefore of enormous value in planning the ablation procedure.²⁷ The initial step in any catheter ablation procedure for ventricular tachycardia is a complete electrophysiological study to identify the location and mechanism of the arrhythmia. It is also important to confirm that the arrhythmia is indeed ventricular tachycardia and not one of the rhythms that can mimic it, such as supraventricular tachycardias with aberrancy (a wide QRS complex with aberrant conduction).

When ventricular tachycardia is confirmed, the mechanism can be defined during the electrophysiological study, and the results will guide the ablation strategy (Fig. 3). Two specific types of ventricular tachycardia that are distinct from most other types are bundle-branch reentrant

ventricular tachycardia (due to a reentry circuit involving the bundle branches of the conduction system) and fascicular ventricular tachycardia (which also originates from the conduction system). Both these entities can be readily identified during the electrophysiological study and treated with focal ablation.²⁸

The primary approach for ablation of focal ventricular tachycardia involves mapping (localizing) the site from which the ventricular tachycardia originates. In “activation mapping,” the electrical signal recorded during ventricular tachycardia from a catheter positioned in the heart can be timed in relation to the earliest point of onset of the body-surface QRS complex; the earlier the recorded signal, the closer the catheter tip is to the site of origin of the ventricular tachycardia. In “pace mapping,” the 12-lead ECG recorded during pacing at a specific site can be compared with the 12-lead ECG recorded during ventricular tachycardia; when the two QRS patterns are similar, the pacing site is likely to be near the site of origin of the ventricular tachycardia. This is also the approach used in mapping PVCs. Once the focus of origin of the ventricular tachycardia has been identified, radiofrequency current can be delivered through the catheter, resulting in ablation of that focus. This approach is very effective for PVCs and idiopathic ventricular tachycardias.²⁵ Occasionally, this type of focal ventricular tachycardia can also be encountered in patients with structural heart disease.²⁹

Sustained ventricular tachycardia due to a reentry circuit involving a myocardial scar tends to involve a large area of the myocardium and to have a defined exit site from the scar into the rest of the myocardium, which can be mapped (if the patient is hemodynamically stable) to identify a suitable ablation site. One scar may have several exit sites, resulting in ventricular tachycardias with different ECG patterns and making ablation of multiple sites necessary. One approach to ablating reentrant ventricular tachycardia is called “entrainment mapping,” which involves use of a pacing catheter to identify areas of a reentrant ventricular tachycardia circuit. The pacing rate is set slightly faster than the rate of the tachycardia, and the pacing catheter is moved from point to point until pacing “captures” the ventricular tachycardia circuit, establishing that the paced location is part of that circuit.³⁰ Termination of ventricular tachycardia is then achieved by radiofrequency ablation of critical parts of the

ventricular tachycardia circuit (such as a narrow channel of conducting tissue) that can be characterized by this approach.^{30,31}

Some patients tend to have clinically significant hemodynamic compromise during ventricular tachycardia, precluding the performance of activation or entrainment mapping during the arrhythmia. The use of electroanatomical images to display the location of scars^{32,33} (“voltage” mapping or “scar” mapping) allows ablation of sites that are potential locations of ventricular tachycardia circuits and makes it possible to perform catheter ablation in patients with hemodynamically unstable ventricular tachycardia.^{34,35} Electroanatomical mapping uses computerized systems that provide three-dimensional display of spatial electrophysiological data on a geometric display of the heart, which is defined by moving the catheter to various regions in the ventricles. The catheter signal is used to measure the local voltage of the depolarization wave (electrogram) during sinus rhythm. Scars are identified on such displays by the presence of very-low-voltage local electrograms or lack of electrograms (Fig. 2). These maps can also be merged with MRI and CT images acquired before the procedure to improve the accuracy of the mapping.

EPICARDIAL MAPPING AND ABLATION

With the use of a percutaneous subxiphoid approach, the pericardial space can be accessed in a closed-chest procedure performed in the cardiac electrophysiology laboratory.³⁶ The pericardial reflections allow free catheter movement on the anterior, apical, posterior, and lateral epicardial surfaces of the ventricles for mapping and ablation. Initially, this approach was used for the management of ventricular tachycardia in patients with Chagas’ heart disease³⁷; it is now routinely used for conditions such as arrhythmogenic right ventricular cardiomyopathy and non-ischemic cardiomyopathy, which tend to have epicardial circuits.^{38,39}

In patients who have pericardial adhesions, most commonly after undergoing cardiac surgical procedures, the pericardial space can be accessed through a surgical subxiphoid window or an anterolateral thoracotomy.⁴⁰ Special precautions are important to ensure safe ablation in an open-chest procedure; for example, independent lung ventilation allows the left lung to be deflated and moved away from the operative field.⁴⁰

ANTICOAGULANT THERAPY

Manipulation of catheters inside the heart and the lesions created during ablation are potentially thrombogenic, and anticoagulant therapy is therefore routinely used for catheter ablation of ventricular tachycardia.⁴¹ During the procedure, heparin is administered by vein (a bolus of 50 to 100 U per kilogram of body weight, followed by infusion, to maintain an activated clotting time above 300 seconds). After the procedure, heparin is restarted once hemostasis has been achieved at access sites. Oral anticoagulant therapy is administered for at least 4 weeks in patients with structural heart disease (and if extensive ablation has been performed).²⁵ Use of long-term anticoagulant therapy should be guided by preexisting indications (e.g., atrial fibrillation or a previous stroke). In the absence of structural heart disease and with a right-side-only ablation, most centers use short-term aspirin therapy without anticoagulation.⁴¹

VENTRICULAR ASSIST DEVICES

Some patients with ventricular tachycardia who have extreme hemodynamic instability require the use of percutaneous ventricular assist devices during catheter ablation, which can provide hemodynamic support and facilitate mapping of unstable ventricular tachycardias.⁴² These devices may also be useful for preprocedure stabilization and management in cases of severe left ventricular dysfunction.⁴³

CATHETER ABLATION OF VENTRICULAR FIBRILLATION

A small subset of patients with idiopathic ventricular fibrillation have PVCs that trigger the arrhythmia. These PVCs can be targeted for catheter ablation.⁴⁴ Catheter ablation can also successfully target PVCs that trigger ventricular fibrillation or ventricular fibrillation storm in patients with structural heart disease (Fig. 3).⁴⁵

CLINICAL OUTCOMES

Catheter ablation for ventricular tachycardia is effective in patients with and patients without structural heart disease.²⁵ In the absence of structural heart disease, success rates of more than 80% have been reported for both sustained ventricular tachycardia and PVCs.^{46,47} In patients with structural heart disease and ICD shocks, the burden of ventricular tachycardia can be reduced

by catheter ablation,²⁶ and ablation can be life-saving in those with ventricular tachycardia storm.¹⁹ The overall success rate with ablation is higher for patients with postinfarction ischemic cardiomyopathy (56 to 77%) than for patients with nonischemic cardiomyopathy (38 to 67%).^{46,47}

Recurrent ventricular tachycardia after ablation in patients with structural heart disease is associated with a decreased chance of survival.^{46,47} Analysis of a retrospective database involving 2061 patients treated at specialized centers for catheter ablation of ventricular tachycardia showed that freedom from recurrence at 1 year was 70% (72% for patients with ischemic cardiomyopathy and 68% for those with nonischemic cardiomyopathy).⁴⁷ Transplantation-free survival at 1 year was 90% among patients without a recurrence of ventricular tachycardia and 71% among patients with a recurrence.

Clinical trials of treatment for ventricular tachycardia have special challenges, since catheter ablation is the only option for many patients, and referral for ablation often occurs relatively late in the natural history of the disease, making randomization ethically problematic.⁴⁷ Several carefully designed randomized trials have shown the superiority of catheter ablation to medical therapy in controlling recurrences of ventricular tachycardia, including the Ventricular Tachycardia Ablation versus Escalated Antiarrhythmic Drug Therapy in Ischemic Heart Disease (VANISH) trial,⁴⁸ the Substrate Mapping and Ablation in Sinus Rhythm to Halt Ventricular Tachycardia (SMASH-VT) trial,⁴⁹ and the Ventricular Tachycardia Ablation in Coronary Heart Disease (VTACH) trial (Table 2).⁵⁰ However, there is a need for randomized trials with sufficient power to assess a mortality end point for catheter ablation of ventricular tachycardia.^{51,52}

COMPLICATIONS

Complications of ventricular tachycardia ablation include access-site vascular injury, cardiac perforation with or without tamponade, procedure-related thromboembolism (which can be symptomatic or asymptomatic), and even death. In a Nationwide Inpatient Sample (NIS) study involving 4653 patients undergoing postinfarction ablation of ventricular tachycardia, 6.9% of the patients had vascular complications, 4.2% had cardiac complications, 0.5% had neurologic complications, and 1.6% died in the hospital.⁵³ In a large, single-center series, 4% of patients with

Table 2. Selected Clinical Trials of VT Ablation.*

Trial	Design	Study Population (Comparison)	No. of Patients	Months of Follow-up†	Outcome
SMASH VT, ⁴⁹ 2007	RCT	Patients with ICM (ICD plus VT ablation vs. ICD alone)	128	22.5±5.5	Ablation superior (incidence of ICD therapy, 12% in ablation group vs. 33% in control group at 2 yr)
VTACH, ⁵⁰ 2010	RCT	Patients with ICM (ICD plus VT ablation vs. ICD alone for stable VT)	107	22.5±9.0	Ablation superior (median time to recurrence of VT or VF, 18.6 mo in ablation group vs. 5.9 mo in control group)
VANISH, ⁴⁸ 2016	RCT	Patients with ICM (VT ablation vs. escalation of antiarrhythmic-drug therapy for drug-refractory VT)	259	27.9±17.1	Ablation superior (primary composite end point of death, VT storm, or appropriate ICD shock, 59.1% in ablation group vs. 68.5% in control group)
Multicenter Thermocool VT Ablation Trial, ²⁶ 2008	Observational	Patients with ICM	231	12	Catheter ablation of VT is a reasonable option for clinical management (freedom from recurrent VT, 53% at 6 mo)
IVTCC, ⁴⁷ 2015	Retrospective	Patients with ICM or NICM	2061	12	Freedom from VT recurrence, 70% at 1 yr; transplantation-free survival, 90% for patients without recurrence vs. 71% for those with recurrence

* ICD denotes implantable cardioverter-defibrillator, ICM ischemic cardiomyopathy, IVTCC International VT Ablation Center Collaborative Group, NICM nonischemic cardiomyopathy, RCT randomized, controlled trial, SMASH-VT Substrate Mapping and Ablation in Sinus Rhythm to Halt Ventricular Tachycardia, VANISH Ventricular Tachycardia Ablation versus Escalated Antiarrhythmic Drug Therapy, VF ventricular fibrillation, and VTACH Ventricular Tachycardia Ablation in Coronary Heart Disease.

† Plus-minus values are means ±SD.

idiopathic ventricular tachycardia had complications, as did up to 6% of patients with structural heart disease.⁵⁴

Some complications are specifically associated with percutaneous epicardial access, such as phrenic nerve damage, coronary-artery injury, liver laceration or hematoma, and right ventricular damage.⁵⁵ Coronary injury can be avoided by careful imaging of the coronary arteries during the procedure. Catheter-based techniques, such as balloon interposition to separate the phrenic nerve from the heart during catheter ablation, can be used to avoid nerve injury.³⁶

Progressive pump failure and a low-output state can occur in patients with advanced heart failure who are undergoing ablation procedures for ventricular tachycardia. These procedures can be prolonged in patients with large scars, and an average duration of more than 5 hours has been reported in clinical trials.²⁶ The long duration of the procedures can have an adverse effect on outcomes and mortality.⁵⁶

MANAGEMENT OF INTRACTABLE VENTRICULAR TACHYCARDIA

Ventricular tachycardia that cannot be effectively controlled with catheter ablation poses a special clinical challenge. In patients with ventricular tachycardias originating in deep intramural locations, specialized approaches for intramural ablation, such as needle ablation and coil embolization, can be used.^{22,23} “Bipolar” ablation of ventricular tachycardia (in which two catheters are positioned on opposite sides of the ventricular wall) has also been successfully used for ventricular tachycardia originating in deep locations.⁵⁷ Since the autonomic nervous system powerfully regulates myocardial electrical propagation, neuromodulation approaches (e.g., thoracic epidural anesthesia and bilateral stellate ganglionectomy) have been used to manage ventricular tachycardia when radiofrequency ablation was unsuccessful.^{58,59} In extreme cases, implantation of a ventricular assist device or heart transplantation may be considered. Biologic approaches such as the use of enzymes to homogenize ventricular scars by interrupting abnormal paths of electrical propagation within the scar,⁶⁰ gene therapy to target connexins that modulate impulse propagation in the heart,⁶¹ and stereotactic radiation therapy⁶² are examples of new therapies that are being experimentally evalu-

ated for modulation of ventricular tachycardia circuits.

CONCLUSIONS

Catheter ablation has become well established in the clinical management of ventricular tachycardia over the past two decades. Ablation has a high rate of success for patients with PVCs and those with idiopathic ventricular tachycardia. Among patients with structural heart disease, success rates are not as high, although technological advancements have resulted in improved outcomes. If ventricular tachycardia is not successfully controlled with catheter ablation or if it recurs despite ablation, the chance of survival is

decreased. New approaches are being developed to try to increase the proportion of patients who can be successfully treated.

Dr. Shivkumar reports receiving grant support from Abbott Medical and holding the following patents, for which he does not receive income: pending U.S. patent number 9,603,674 on a method to protect the esophagus and other mediastinal structures during cardiac and thoracic interventions, issued U.S. patent number 7,871,408 on methods and systems for gated or pulsed application of ablative energy in the treatment of cardiac disorders, pending U.S. patent number 14/581,388 on a transseptal access device and methods, and pending U.S. patent number 14/706,312 on a system and method for modulation of cardiac tissue. No other potential conflict of interest relevant to this article was reported.

Disclosure forms provided by the author are available with the full text of this article at NEJM.org.

I thank the faculty, staff, and trainees at the UCLA Cardiac Arrhythmia Center and the UCLA Department of Medicine for their support and thoughtful comments.

REFERENCES

1. Bayés de Luna A, Coumel P, Leclercq JF. Ambulatory sudden cardiac death: mechanisms of production of fatal arrhythmia on the basis of data from 157 cases. *Am Heart J* 1989;117:151-9.
2. Al-Khatib SM, Stevenson WG, Ackerman MJ, et al. 2017 AHA/ACC/HRS guideline for management of patients with ventricular arrhythmias and the prevention of sudden cardiac death: a report of the American College of Cardiology/American Heart Association Task Force on Clinical Practice Guidelines and the Heart Rhythm Society. *J Am Coll Cardiol* 2018; 72(14):e91-e220.
3. Miller JM, Marchlinski FE, Harken AH, Hargrove WC, Josephson ME. Subendocardial resection for sustained ventricular tachycardia in the early period after acute myocardial infarction. *Am J Cardiol* 1985; 55:980-4.
4. Hartzler GO. Electrode catheter ablation of refractory focal ventricular tachycardia. *J Am Coll Cardiol* 1983;2:1107-13.
5. Morady F. Radio-frequency ablation as treatment for cardiac arrhythmias. *N Engl J Med* 1999;340:534-44.
6. Pedersen CT, Kay GN, Kalman J, et al. EHRA/HRS/APHRS expert consensus on ventricular arrhythmias. *Heart Rhythm* 2014;11(10):e166-e196.
7. Stevenson WG. Current treatment of ventricular arrhythmias: state of the art. *Heart Rhythm* 2013;10:1919-26.
8. Roberts-Thomson KC, Lau DH, Sanders P. The diagnosis and management of ventricular arrhythmias. *Nat Rev Cardiol* 2011;8:311-21.
9. Rutherford SL, Trew ML, Sands GB, LeGrice IJ, Smaill BH. High-resolution 3-dimensional reconstruction of the infarct border zone: impact of structural remodeling on electrical activation. *Circ Res* 2012;111:301-11.
10. de Bakker JM, van Capelle FJ, Janse MJ, et al. Slow conduction in the infarcted human heart: 'zigzag' course of activation. *Circulation* 1993;88:915-26.
11. de Bakker JM, van Capelle FJ, Janse MJ, et al. Macroreentry in the infarcted human heart: the mechanism of ventricular tachycardias with a "focal" activation pattern. *J Am Coll Cardiol* 1991;18:1005-14.
12. Nakahara S, Tung R, Ramirez RJ, et al. Characterization of the arrhythmogenic substrate in ischemic and nonischemic cardiomyopathy: implications for catheter ablation of hemodynamically unstable ventricular tachycardia. *J Am Coll Cardiol* 2010;55:2355-65.
13. Koplan BA, Soejima K, Baughman K, Epstein LM, Stevenson WG. Refractory ventricular tachycardia secondary to cardiac sarcoid: electrophysiologic characteristics, mapping, and ablation. *Heart Rhythm* 2006;3:924-9.
14. Santangeli P, Zado ES, Supple GE, et al. Long-term outcome with catheter ablation of ventricular tachycardia in patients with arrhythmogenic right ventricular cardiomyopathy. *Circ Arrhythm Electrophysiol* 2015;8:1413-21.
15. Vaseghi M, Shivkumar K. The role of the autonomic nervous system in sudden cardiac death. *Prog Cardiovasc Dis* 2008; 50:404-19.
16. Bogun F, Crawford T, Reich S, et al. Radiofrequency ablation of frequent, idiopathic premature ventricular complexes: comparison with a control group without intervention. *Heart Rhythm* 2007;4:863-7.
17. Latchamsetty R, Bogun F. Premature ventricular complex ablation in structural heart disease. *Card Electrophysiol Clin* 2017;9:133-40.
18. Lakkireddy D, Di Biase L, Ryschon K, et al. Radiofrequency ablation of premature ventricular ectopy improves the efficacy of cardiac resynchronization therapy in nonresponders. *J Am Coll Cardiol* 2012; 60:1531-9.
19. Carbucicchio C, Santamaria M, Trevisi N, et al. Catheter ablation for the treatment of electrical storm in patients with implantable cardioverter-defibrillators: short- and long-term outcomes in a prospective single-center study. *Circulation* 2008;117:462-9.
20. Bogun FM, Desjardins B, Good E, et al. Delayed-enhanced magnetic resonance imaging in nonischemic cardiomyopathy: utility for identifying the ventricular arrhythmia substrate. *J Am Coll Cardiol* 2009;53:1138-45.
21. Haqqani HM, Tschabrunn CM, Tzou WS, et al. Isolated septal substrate for ventricular tachycardia in nonischemic dilated cardiomyopathy: incidence, characterization, and implications. *Heart Rhythm* 2011;8:1169-76.
22. Sapp JL, Breeckler C, Pike R, et al. Initial human feasibility of infusion needle catheter ablation for refractory ventricular tachycardia. *Circulation* 2013;128:2289-95.
23. Tholakanahalli VN, Bertog S, Roukoz H, Shivkumar K. Catheter ablation of ventricular tachycardia using intracoronary wire mapping and coil embolization: description of a new technique. *Heart Rhythm* 2013;10:292-6.
24. Tung R, Bauer B, Schelbert H, et al. Incidence of abnormal positron emission tomography in patients with unexplained cardiomyopathy and ventricular arrhythmias: the potential role of occult inflammation in arrhythmogenesis. *Heart Rhythm* 2015;12:2488-98.
25. Aliot EM, Stevenson WG, Almendral-Garrote JM, et al. EHRA/HRS expert consensus on catheter ablation of ventricular arrhythmias: developed in a partnership

- with the European Heart Rhythm Association (EHRA), a registered branch of the European Society of Cardiology (ESC), and the Heart Rhythm Society (HRS): in collaboration with the American College of Cardiology (ACC) and the American Heart Association (AHA). *Heart Rhythm* 2009;6:886-933.
26. Stevenson WG, Wilber DJ, Natale A, et al. Irrigated radiofrequency catheter ablation guided by electroanatomic mapping for recurrent ventricular tachycardia after myocardial infarction: the Multicenter Thermocool Ventricular Tachycardia Ablation Trial. *Circulation* 2008;118:2773-82.
 27. Miller JM, Jain R, Dandamudi G, Kambur TR. Electrocardiographic localization of ventricular tachycardia in patients with structural heart disease. *Card Electrophysiol Clin* 2017;9:1-10.
 28. Lopera G, Stevenson WG, Soejima K, et al. Identification and ablation of three types of ventricular tachycardia involving the His-Purkinje system in patients with heart disease. *J Cardiovasc Electrophysiol* 2004;15:52-8.
 29. Das MK, Scott LR, Miller JM. Focal mechanism of ventricular tachycardia in coronary artery disease. *Heart Rhythm* 2010;7:305-11.
 30. Stevenson WG, Soejima K. Catheter ablation for ventricular tachycardia. *Circulation* 2007;115:2750-60.
 31. Tung R, Mathuria N, Michowitz Y, et al. Functional pace-mapping responses for identification of targets for catheter ablation of scar-mediated ventricular tachycardia. *Circ Arrhythm Electrophysiol* 2012;5:264-72.
 32. Cesario DA, Vaseghi M, Boyle NG, et al. Value of high-density endocardial and epicardial mapping for catheter ablation of hemodynamically unstable ventricular tachycardia. *Heart Rhythm* 2006;3:1-10.
 33. Hsia HH, Callans DJ, Marchlinski FE. Characterization of endocardial electrophysiological substrate in patients with nonischemic cardiomyopathy and monomorphic ventricular tachycardia. *Circulation* 2003;108:704-10.
 34. Jaïs P, Maury P, Khairy P, et al. Elimination of local abnormal ventricular activities: a new end point for substrate modification in patients with scar-related ventricular tachycardia. *Circulation* 2012;125:2184-96.
 35. Nakahara S, Tung R, Ramirez RJ, et al. Distribution of late potentials within infarct scars assessed by ultra high-density mapping. *Heart Rhythm* 2010;7:1817-24.
 36. Boyle NG, Shivkumar K. Epicardial interventions in electrophysiology. *Circulation* 2012;126:1752-69.
 37. Sosa E, Scanavacca M, D'Avila A, Bellotti G, Pilleggi F. Radiofrequency catheter ablation of ventricular tachycardia guided by nonsurgical epicardial mapping in chronic Chagas heart disease. *Pacing Clin Electrophysiol* 1999;22:128-30.
 38. Sacher F, Roberts-Thomson K, Maury P, et al. Epicardial ventricular tachycardia ablation: a multicenter safety study. *J Am Coll Cardiol* 2010;55:2366-72.
 39. Tung R, Michowitz Y, Yu R, et al. Epicardial ablation of ventricular tachycardia: an institutional experience of safety and efficacy. *Heart Rhythm* 2013;10:490-8.
 40. Michowitz Y, Mathuria N, Tung R, et al. Hybrid procedures for epicardial catheter ablation of ventricular tachycardia: value of surgical access. *Heart Rhythm* 2010;7:1635-43.
 41. Blanc JJ, Almendral J, Brignole M, et al. Consensus document on antithrombotic therapy in the setting of electrophysiological procedures. *Europace* 2008;10:513-27.
 42. Reddy YM, Chinitz L, Mansour M, et al. Percutaneous left ventricular assist devices in ventricular tachycardia ablation: multicenter experience. *Circ Arrhythm Electrophysiol* 2014;7:244-50.
 43. Mathuria N, Wu G, Rojas-Delgado F, et al. Outcomes of pre-emptive and rescue use of percutaneous left ventricular assist device in patients with structural heart disease undergoing catheter ablation of ventricular tachycardia. *J Interv Card Electrophysiol* 2017;48:27-34.
 44. Knecht S, Sacher F, Wright M, et al. Long-term follow-up of idiopathic ventricular fibrillation ablation: a multicenter study. *J Am Coll Cardiol* 2009;54:522-8.
 45. Marrouche NF, Verma A, Wazni O, et al. Mode of initiation and ablation of ventricular fibrillation storms in patients with ischemic cardiomyopathy. *J Am Coll Cardiol* 2004;43:1715-20.
 46. Dinov B, Fiedler L, Schönbauer R, et al. Outcomes in catheter ablation of ventricular tachycardia in dilated nonischemic cardiomyopathy compared with ischemic cardiomyopathy: results from the Prospective Heart Centre of Leipzig VT (HELP-VT) Study. *Circulation* 2014;129:728-36.
 47. Tung R, Vaseghi M, Frankel DS, et al. Freedom from recurrent ventricular tachycardia after catheter ablation is associated with improved survival in patients with structural heart disease: an International VT Ablation Center Collaborative Group study. *Heart Rhythm* 2015;12:1997-2007.
 48. Sapp JL, Wells GA, Parkash R, et al. Ventricular tachycardia ablation versus escalation of antiarrhythmic drugs. *N Engl J Med* 2016;375:111-21.
 49. Reddy YV, Reynolds MR, Neuzil P, et al. Prophylactic catheter ablation for the prevention of defibrillator therapy. *N Engl J Med* 2007;357:2657-65.
 50. Kuck KH, Schaumann A, Eckardt L, et al. Catheter ablation of stable ventricular tachycardia before defibrillator implantation in patients with coronary heart disease (VTACH): a multicentre randomised controlled trial. *Lancet* 2010;375:31-40.
 51. Pokorney SD, Friedman DJ, Calkins H, et al. Catheter ablation of ventricular tachycardia: lessons learned from past clinical trials and implications for future clinical trials. *Heart Rhythm* 2016;13:1748-54.
 52. ClinicalTrials.gov. Ventricular tachycardia. 2018 (<https://clinicaltrials.gov/ct2/results?term=ventricular+tachycardia&Search=Search>).
 53. Palaniswamy C, Kolte D, Harikrishnan P, et al. Catheter ablation of postinfarction ventricular tachycardia: ten-year trends in utilization, in-hospital complications, and in-hospital mortality in the United States. *Heart Rhythm* 2014;11:2056-63.
 54. Bohnen M, Stevenson WG, Tedrow UB, et al. Incidence and predictors of major complications from contemporary catheter ablation to treat cardiac arrhythmias. *Heart Rhythm* 2011;8:1661-6.
 55. Koruth JS, Aryana A, Dukkipati SR, et al. Unusual complications of percutaneous epicardial access and epicardial mapping and ablation of cardiac arrhythmias. *Circ Arrhythm Electrophysiol* 2011;4:882-8.
 56. Yu R, Ma S, Tung R, et al. Catheter ablation of scar-based ventricular tachycardia: relationship of procedure duration to outcomes and hospital mortality. *Heart Rhythm* 2015;12:86-94.
 57. Kumar S, Tedrow UB, Stevenson WG. Adjunctive interventional techniques when percutaneous catheter ablation for drug refractory ventricular arrhythmias fail: a contemporary review. *Circ Arrhythm Electrophysiol* 2017;10(2):e003676.
 58. Shivkumar K, Ajjola OA, Anand I, et al. Clinical neurocardiology defining the value of neuroscience-based cardiovascular therapeutics. *J Physiol* 2016;594:3911-54.
 59. Vaseghi M, Barwad P, Malavassi Corrales FJ, et al. Cardiac sympathetic denervation for refractory ventricular arrhythmias. *J Am Coll Cardiol* 2017;69:3070-80.
 60. Yagishita D, Ajjola OA, Vaseghi M, et al. Electrical homogenization of ventricular scar by application of collagenase: a novel strategy for arrhythmia therapy. *Circ Arrhythm Electrophysiol* 2013;6:776-83.
 61. Greener ID, Sasano T, Wan X, et al. Connexin43 gene transfer reduces ventricular tachycardia susceptibility after myocardial infarction. *J Am Coll Cardiol* 2012;60:1103-10.
 62. Cuculich PS, Schill MR, Kashani R, et al. Noninvasive cardiac radiation for ablation of ventricular tachycardia. *N Engl J Med* 2017;377:2325-36.

Copyright © 2019 Massachusetts Medical Society.